

MINISTRY OF PUBLIC HEALTH OF UKRAINE

Department of human resources policy, education and science

Testing Board

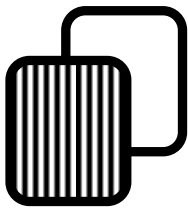
Student ID									

Last name									

Variant _____

Test items for licensing examination

Krok 2 MEDICINE



General Instruction

Every one of these numbered questions or unfinished statements in this chapter corresponds to answers or statements endings. Choose the answer (finished statements) that fits best and fill in the circle with the corresponding Latin letter on the answer sheet.

Authors of items: Afanasievskaya M.S., Baburina O.A., Bahirian I.O., Bedeniuk A.D., Beriozov V.M., Besh L.V., Beziuk M.M., Bezruk T.O., Bielska O.A., Bilyk V.D., Bobrytska V.V., Borysova T.P., Budaieva I.V., Bukhtieieva E.R., Bukhtiyarova O.H., Buriak O.H., Butina L.I., Chaika O.O., Chebanenko R.O., Chemodanov E.B., Chichirelio-Konstantynovych K.D., Chuiko A.P., Dankyna I.A., Davydenko O.M., Desiatska Yu.V., Detsyk O.Z., Dobrovolska L.M., Dotsenko T.M., Dovhaliuk Yu.P., Duplenko P.Yu., Furman V.M., Halicheva N.O., Harahulia I.S., Herasymenko O.I., Hlumcher F.S., Hnatko O.P., Honcharova I.M., Hordieieva H.D., Hresko M.M., Hyrla Ya.V., Ivakhno O.P., Ivanchuk P.R., Kadochnykov V.S., Kalinovska I.V., Kalsada I.N., Kalutsky I.V., Kandyba V.P., Kanikovskyy O.Ye., Kanovska L.V., Karliyuchuk O.O., Khomaziuk T.A., Kitura O.Ye., Koliush O.I., Koloskova O.K., Koltsova N.I., Kompaniyets K.M., Kondratenko P.H., Kondratiev V.O., Konopliova L.F., Konovalova N.V., Kopchak O.V., Korniyets N.H., Korobchansky V.O., Korobko O.A., Kovalchuk P.Ye., Kovtun A.I., Kriachkova L.V., Krylova V.Yu., Kucherenko O.S., Kudelia I.V., Kudintseva T.Z., Kudrevych O.M., Kudria V.I., Kuzmenko S.A., Lakusta N.M., Lavrinchuk I.O., Lebediuk M.M., Leshchenko K.A., Loskutova I.Ye., Lysenko D.A., Makieieva N.I., Malkovych N.M., Martynik Ye.M., Martyniuk L.P., Mavrutenkov V.V., Mazorchuk S.H., Medvediev M.V., Miakinkova L.O., Mierkulova N.F., Mitunina N.I., Mostovy Yu.M., Mysak A.I., Nadraha O.B., Nechytailo Yu.M., Nykoniuk T.R., Osetrova M.S., Osiadla E.S., Ospanova T.S., Ostropolets M.S., Ostrovsky I.M., Pavlovych L.V., Petriuk B.V., Pisotska L.A., Prus L.O., Pryshliak O.Ya., Radchenko O.M., Radutna O.A., Rak L.M., Reva V.B., Riabenko E.B., Riapolova T.L., Romanenko V.N., Rud V.O., Seleznova S.V., Semeniak A.V., Semenukha K.V., Serheta I.V., Shapkin V.Ye., Shcherbinin O.V., Shkondina O.F., Shkrobanets I.D., Shorikov Ye.I., Shostakovych-Koretska L.R., Shtyker S.Yu., Shumko B.I., Shvyhar L.V., Sikorska M.V., Slipechko Yu.M., Slyva V.I., Smoliak L.L., Soboleva N.P., Sokolov O.B., Soldak I.I., Soloviov I.Ye., Sorochan V.V., Sotnik Yu.P., Suk V.H., Sushkov M.T., Sychova V.V., Sylenko H.Ia., Synoverska O.B., Syvozhelezov A.V., Talalaienko Yu.O., Todoriko L.D., Tokariyev A.V., Tonkohlas O.A., Toropchyn V.I., Troian V.I., Tsariova N.M., Tsertiy V.P., Tsiapa N.A., Tsyvenko O.I., Tuchkina I.O., Vankhanen V.D., Volianska A.H., Vorokhta Yu.M., Yakovenko I.K., Yermolenko T.O., Yurieva L.M., Zakharchenko Yu.B., Zheliba M.D., Znachurenko L.S., Zotov O.S. and Committees of professional expertise

Item reviewers. Ahafonova O.O., Anisimov Ye.M., Babiak T.Ye., Bobrytska V.V., Borysova T.M., Chursina T.Ya., Dyndar O.A., Holovanova I.A., Hryhorov Yu.B., Hubka V.O., Hutsalenko O.O., Kalinina S.Yu., Kanikovskyy O.Ye., Karapetian K.H., Khomaziuk T.A., Kolesnyk O.M., Koloskova O.K., Kolosovych I.V., Kopcha V.S., Kravchenko O.V., Kutovy O.B., Kuzmina I.Yu., Malanchuk L.M., Martyniuk L.P., Mavrutenkov V.V., Medvediev M.V., Mishchenko V.P., Moroz L.V., Muravska O.M., Petrushenko V.V., Prokhorova M.P., Pryshliak O.Ya., Puzanova O.H., Pyptiuk O.V., Radchenko O.M., Shestakova I.V., Stovban I.V., Sydoruk R.I., Tsvirenko S.M., Usenko S.H., Vakaliuk I.P., Volianska A.H.

The book includes test items for use at licensing integrated examination "Krok 2. Medicine" and further use in teaching.

The book has been developed for students of medical, pediatric and medical-and-prophylactic faculties and academic staff of higher medical educational establishments.

Approved by Ministry of Public Health of Ukraine as examination and teaching publication based on expert conclusions (Orders of MPH of Ukraine of 14.08.1998 №251, of 27.12.1999 №303, of 16.10.2002 №374, of 29.05.2003 №233).

1. A patient with Morgagni-Adams-Stokes syndrome has fainted when walking up the stairs. The skin is pale, the pupils are dilated, tonic spasms are observed, rib cage is immobile. Make the diagnosis:

- A. Clinical death
- B. Social death
- C. Preagony
- D. Agony
- E. Biological death

2. A 32-year-old welder complains of weakness and fever. His illness initially presented as tonsillitis one month earlier. On examination: temperature - 38.9°C , respirations - 24/min., pulse - 100/min., blood pressure - 100/70 mm Hg, hemorrhages on the legs, enlargement of the lymph nodes. Complete blood count shows Hb- 70 g/L, RBC- $2.2 \cdot 10^{12}/\text{L}$, WBC- $3.0 \cdot 10^9/\text{L}$ with 32% of blasts, 1% of eosinophiles, 3% of bands, 36% of segments, 20% of lymphocytes, and 8% of monocytes, ESR- 47 mm/hour. What is the cause of anemia in this case?

- A. Acute leukemia
- B. Chronic lympholeukemia
- C. Aplastic anemia
- D. B_{12} -deficient anemia
- E. Chronic hemolytic anemia

3. After a 5-day-long celebration of his daughter's wedding a 65-year-old patient "saw" in his yard many cats, chickens, and rats. He tried to chase them away, but was scared off when the animals started scolding him and tried to harm him. What is the likely diagnosis?

- A. Delirium tremens
- B. Senile psychosis
- C. Schizophrenia
- D. Organic brain syndrome
- E. Reactive hallucinosis

4. A regional cardiologist is given a task to develop a plan for preventive measures aimed at decreasing cardiovascular mortality rates. What measures should be planned for secondary prevention?

- A. Prevention of recurrences and complications
- B. Referring patients for sanatorium-and-spa treatment
- C. Prevention of diseases
- D. Referring patients for inpatient treatment
- E. Optimization of lifestyle and living conditions

5. During physical exertion a man suddenly developed acute chest pain on the right and dyspnea. Objectively he assumes forced half-sitting position in the bed, presents with diffuse cyanosis, resting tachypnea of 38/min., the right side of the thorax is enlarged and does not participate in the respiratory process; percussion on the right reveals tympanic resonance and absence of respiration. What is the most likely diagnosis in this case?

- A. Spontaneous pneumothorax
- B. Hemothorax
- C. Lobar pneumonia
- D. Pulmonary embolism
- E. Acute pleurisy

6. A 34-year-old man on the 3rd day of ceftriaxone treatment for acute otitis (daily dosage - 2 grams) developed diarrhea occurring 5-6 times per day. Feces are without mucus or blood admixtures. Temperature is 36.6°C . Gregersen reaction (occult blood in feces) is negative. Stool culture detected no pathogenic germs. What is the most likely cause of diarrhea in this case?

- A. Antibiotic-associated diarrhea
- B. Intestinal dysbiosis
- C. Bacterial overgrowth syndrome
- D. Ulcerative colitis
- E. Crohn's disease (regional enteritis)

7. A 24-year-old patient visited a doctor complaining of enlargement of his submaxillary lymph nodes. Objectively: submaxillary, axillary and inguinal lymph nodes are enlarged. Chest X-ray shows: enlarged lymph nodes of mediastinum. Blood test: erythrocytes - $3.4 \cdot 10^{12}/\text{L}$, Hb- 100 g/L, blood colour index - 0.88, platelets - $190 \cdot 10^9/\text{L}$, leucocytes - $7.5 \cdot 10^9/\text{L}$, eosinophiles - 8%, band neutrophils - 2%, segmented neutrophils - 67%, lymphocytes - 23%, ESR - 22 mm/hour. What test must be prescribed to verify the cause of lymphadenopathy?

- A. Open biopsy of the lymph nodes
- B. Abdominal US
- C. Mediastinum tomography
- D. Puncture biopsy of the lymph nodes
- E. Sternal puncture

8. During medical examination a cadet in the naval college was detected to have a painless dense ulcer 1.5x0.5 in size in his perianal area at the 2 o'clock position. The ulcer floor resembles "old fat". What is the provisional diagnosis?

- A. Hard syphilitic chancre of the rectum
- B. Rectal fissure
- C. Rectal fistula
- D. Anal cancer
- E. Anal crypt suppuration

9. A 7-year-old boy has severe pulmonary mucoviscidosis (cystic fibrosis). He complains of dyspnea and blood expectoration. Objectively he presents with lagging physical development, acrocyanosis, hepatomegaly, drumstick fingers, and nail plates resembling a "clock face". Provisional diagnosis of chronic pulmonary heart disease is made. What examination would be the most informative for diagnosis confirmation?

- A. Doppler echocardiography
- B. Electrocardiography
- C. Chest X-ray
- D. Rheography of the pulmonary artery
- E. Ultrasound of the liver

10. A 10-year-old boy, who was outdoors in windy and cold weather, developed moderate pain and tingling in his fingers and toes. When he had returned home, his parents noticed that the tips of his fingers and toes were white and their sensitivity was lost. The affected areas are warming up, the fingers are tingling and in pain. Skin pallor changed into redness, tingling stopped, slight itching and swelling of the fingers appeared. Determine the frostbite degree in this child:

- A.** Frostbite of the I degree
- B.** Perniosis
- C.** Frostbite of the II degree
- D.** Frostbite of the III degree
- E.** Frostbite of the IV degree

11. A 25-year-old woman complains of fatigue, dizziness, hemorrhagic rashes on the skin. She has been presenting with these signs for a month. Blood test: erythrocytes - $1.0 \cdot 10^{12}/L$, Hb- 37 g/L, colour index - 1.1, leukocytes - $1.2 \cdot 10^9/L$, platelets - $42 \cdot 10^9/L$. What analysis would be the most advisable for diagnosis-making in this case?

- A.** Sternal puncture (bone marrow biopsy)
- B.** Splenic biopsy
- C.** Liver biopsy
- D.** Coagulation studies
- E.** US of the gastrointestinal tract

12. A 12-year-old boy with hypertrophic cardiomyopathy complains of dyspnea caused by the slightest physical exertion. Echocardiography detected asymmetrical left ventricular hypertrophy, signs of pulmonary hypertension, and left ventricular dilatation, its ejection fraction is 59%. These developments are indicative of:

- A.** Heart failure with preserved ejection fraction
- B.** Heart failure with reduced ejection fraction
- C.** Primary pulmonary hypertension
- D.** Essential hypertension
- E.** Symptomatic arterial hypertension

13. A 35-year-old man complains of rapidly increasing fatigue, palpitations, "visual snow", dizziness. He has a history of peptic ulcer of the stomach. Objectively the skin is pale. Vesicular respiration is observed in the lungs. Systolic murmur is detected over the cardiac apex, heart rate is 100/min., BP is 100/70 mm Hg. The epigastrium is slightly tender on palpation. Blood test: erythrocytes - $3.2 \cdot 10^{12}/L$, Hb- 100 g/L, color index - 0.94. What type of anemia is the most likely present in this case?

- A.** Posthemorrhagic anemia
- B.** Sideroblastic anemia
- C.** Iron-deficiency anemia
- D.** Hemolytic anemia
- E.** Hypoplastic anemia

14. A 35-year-old patient has been suffering from an illness for 3 days. 5 days ago he returned from a trip to Africa. The onset of disease was accompanied by fever up to $40^{\circ}C$,

chills, acute headache, myalgia. In the axillary region the lymph node enlarged up to 3×6 cm can be palpated. The lymph node is dense, intensely painful, slightly mobile, without clear margins; the skin over the node is hyperemic and tight. Tachycardia is present. Make the preliminary diagnosis:

- A.** Plague
- B.** Sepsis
- C.** Tularemia
- D.** Lymphadenitis
- E.** Anthrax

15. Caries morbidity rate is 89% among residents of a community. It is determined that fluorine content in water is 0.1 mg/L. What preventive measures should be taken?

- A.** Water fluorination
- B.** Tooth brushing
- C.** Fluorine inhalations
- D.** Sealant application
- E.** Introduce more vegetables to the diet

16. During appointment with the doctor a man complains of painful itching rashes that appeared on his skin under the beard and moustache one year ago, with frequent exacerbations occurring throughout the year. Objectively the skin of the facial hair growth areas is bluish-purple, thickened, with pustules, erosions, and scabs covering its moist surface. The fistulous tracts are surrounded by the area of loose pink-red granulation and discharge pus. The skin resembles mulberry in appearance. Make the diagnosis:

- A.** Sycosis
- B.** Acne rosacea
- C.** Lupus erythematosus
- D.** Deep trichophytosis
- E.** Tuberculous lupus

17. A 60-year-old man presents with ischemic heart disease and heart failure of the IV class according to NYHA (New York Heart Association) that manifests as dyspnea at rest. There are moist crackles in the patient's lungs. Liver +4 cm, lower limbs are swollen. Ejection fraction is 25%. What sign is the most indicative when determining functional class of heart failure according to NYHA?

- A.** Degree of dyspnea
- B.** Moist crackles in the lungs
- C.** Swollen lower limbs
- D.** Decrease of ejection fraction
- E.** Extent of liver enlargement

18. A 39-year-old man, a battery attendant, suddenly developed weakness, loss of appetite, nonlocalized colicky abdominal pains, and nausea. Objectively his skin is gray; there is pink-gray stripe on his gums; the stomach is soft and sharply painful. Blood test detected erythrocytes with basophilic stippling and anemia. The patient has a history of peptic ulcer disease of the stomach. There is tendency to constipation. What is the most likely provisional diagnosis?

- A. Saturnism (lead poisoning)
- B. Acute appendicitis
- C. Perforation of gastric ulcer
- D. Acute cholecystitis
- E. Chronic alcoholism

19. A 9-month-old infant presents with delayed tooth eruption and fontanel closure, weakness, and excessive sweating. What type of hypovitaminosis is the most likely in this child?

- A. Hypovitaminosis D
- B. Hypovitaminosis C
- C. Hypovitaminosis B₁
- D. Hypovitaminosis B₆
- E. Hypovitaminosis A

20. A 10-year-old girl exhibits high level of physical development ($M + 3\sigma$), her body length increased by 10 cm within a year (which is double the norm for her age group), the number of permanent teeth corresponds with the age norm (20), the development of her secondary sex characteristics is three years ahead of her age (Ma, P, Ax, Menarche). Development rate ahead of her biological age can occur due to:

- A. Endocrine disorders
- B. Acceleration
- C. Certain components of her diet
- D. Sports training
- E. Deficient hygienic education

21. An infant has been born at the 41st week of gestation. The pregnancy was complicated with severe gestosis of the second semester. The weight of the baby is 2400 g, the height is 50 cm. Objectively: the skin is flabby, the layer of subcutaneous fat is thin, hypomyotonia, neonatal reflexes are weak. The internal organs are without pathologic changes. This newborn can be assessed as a:

- A. Full-term infant with intrauterine growth retardation
- B. Premature infant
- C. Immature infant
- D. Postmature infant
- E. Full-term infant with normal body weight

22. A patient suffering from infiltrative pulmonary tuberculosis was prescribed streptomycin, rifampicin, isoniazid, pyrazinamide, vitamin C. One month after the beginning of the treatment the patient started complaining of reduced hearing and tinnitus. What drug has such a side effect?

- A. Streptomycin
- B. Isoniazid
- C. Rifampicin
- D. Pyrazinamide
- E. Vitamin C

23. The doctor has an appointment with a patient, who 2 days ago developed severe chest pain on the left, general weakness, high temperature, and headache. Objectively along the 4th and

5th intercostal nerves on the left the skin is hyperemic and there are tight clusters of small vesicles filled with clear serous content. What is the most likely diagnosis?

- A. Herpes zoster
- B. Herpes simplex
- C. Streptococcal impetigo
- D. Pemphigus
- E. Dermatitis herpetiformis (Dühring's disease)

24. A worker of a blowing shop complains of headache, irritability, sight impairment - he sees everything as if through a "net". Objectively: hyperemic sclera, thickened cornea, decreased opacity of pupils, visual acuity is 0.8 in the left eye, 0.7 in the right eye. The worker uses no means of personal protection. What diagnosis is the most likely?

- A. Cataract
- B. Conjunctivitis
- C. Keratitis
- D. Blepharospasm
- E. Progressive myopia

25. For a week a 42-year-old patient has been suffering from fever attacks followed by high temperature, which occur every 48 hours. Body temperature raises up to 40°C and decreases in 3-4 hours with excessive sweating. The patient presents with loss of appetite and general fatigue. The skin is pale and sallow. The liver and spleen are enlarged and dense on palpation. What method of diagnosis verification would be most efficient?

- A. Microscopy of blood smear and thick blood film
- B. Complete blood count
- C. Bacteriological analysis
- D. Immune-enzyme assay
- E. Microscopy of hanging blood drop

26. A 16-year-old adolescent living in a rural area has been bitten in the shin by a stray dog. The wound is superficial. Regular vaccination against tetanus was received 3 months ago. What treatment tactics would be the most advisable in this case?

- A. Antirabies vaccination
- B. Antirabies immunoglobulin
- C. Tetanus toxoid adsorbed
- D. Antitetanus serum
- E. Antitetanus immunoglobulin

27. A 26-year-old woman is suspected to suffer from systemic lupus erythematosus with systemic lesions of skin, vessels, joints, serous tunics, and heart tissue that developed after photosensitization. The following is detected in blood analysis: LE cells, antibodies to native ds-DNA, isolated anti-centromere antibodies, rheumatoid factor is 1:100, Wassermann reaction is positive, circulating immune complex is 120 units. What immunological indicators are considered to be specific to this disease?

- A. ds-DNA antibodies
- B. Rheumatoid factor
- C. Anti-centromere antibodies
- D. Immunoglobulin A
- E. Increased circulating immune complex

28. A group of 5 had been resting in a forest, they were drinking alcohol and eating canned mushrooms and cured fish. The next day two of them were hospitalized with disturbed vision, swallowing and respiration; the third one presented with acute general weakness and dry mouth. The remaining two were healthy. A tick was detected on the skin of one of the healthy group members. What is the most likely diagnosis?

- A. Botulism
- B. Tick-borne encephalitis
- C. Alcohol poisoning
- D. Mushroom poisoning
- E. Lyme borreliosis

29. A 23-year-old man complains of facial edema, headache, dizziness, low urinary output, urine discoloration (dark red). These complaints arose after the patient had had a case of acute tonsillitis. On examination there are facial edema, the skin is pale, temperature is 37.4°C ; heart rate is 86/min., blood pressure is 170/110 mm Hg. Heart sounds are muffled, the II heart sound is accentuated over the aorta. What etiological factor is the most likely in this case?

- A. Beta-hemolytic streptococcus
- B. Staphylococcus aureus
- C. Streptococcus viridans
- D. Streptococcus pyogenes
- E. Staphylococcus saprophyticus

30. During examination a 4-month-old child with meningococemia presents with acrocyanosis, cold extremities, tachypnea, and thready pulse, blood pressure of 30/0 mm Hg, anuria, and sopor. What clinical syndrome is it?

- A. Septic shock
- B. Neurotoxicosis
- C. Exicosis
- D. Encephalic syndrome
- E. Acute renal failure

31. The pregnancy is full term. The body weight of the parturient woman is 62 kg. Fetus is in a longitudinal lie, the head is engaged to the pelvic inlet. Belly circumference is 100 cm. Uterine fundus height is 35 cm. What body weight of the fetus can be expected?

- A. 3.5 kg
- B. 4 kg
- C. 2.5 kg
- D. 3 kg
- E. 4.5 kg

32. An 18-year-old young man complains of pain in his knee and elbow joints and body temperature up to 39.5°C . One week and a half earlier developed sore throat. On examination his body temperature is 38.5°C . Swelling of the knee and elbow joints is observed. Pulse

is 106/min., rhythmic. Blood pressure is 90/60 mm Hg. Cardiac borders are unchanged, heart sounds are weakened, at the cardiac apex there is soft systolic murmur. What factor would be the most indicative of the likely disease etiology?

- A. Anti-streptolysin O
- B. C-reactive protein
- C. Creatine kinase
- D. Rheumatoid factor
- E. Seromucoid

33. A 20-year-old patient complains of severe headache, double vision, weakness, fever, irritability. Objectively: body temperature is 38.1°C , the patient is reluctant to contact, sensitive to stimuli. There are ptosis of the left eyelid, exotropia, anisocoria S>D, pronounced meningeal syndrome. On lumbar puncture the cerebrospinal fluid flowed out under a pressure of 300 mm Hg, the fluid is clear, slightly opalescent. 24 hours later there appeared fibrin film. Protein - 1.4 g/L, lymphocytes - 600/3 per mm^3 , sugar - 0.3 mmol/L. What is the provisional diagnosis?

- A. Tuberculous meningitis
- B. Meningococcal meningitis
- C. Lymphocytic (Armstrong's) meningitis
- D. Syphilitic meningitis
- E. Mumps meningitis

34. A 32-year-old woman complains of increasing spastic pains in her lower abdomen that occur after emotional stress. Bowel movements are intermittent: 2-3 defecations after waking in the morning alternate with constipations that last for 1-2 days. Objectively body mass is retained, palpation of the sigmoid colon is moderately painful. Hb- 130 g/L, leukocytes - 5.2 g/L, ESR- 9 mm/hour. Rectoromanoscopy is painful due to spastic condition of the intestine, intestinal mucosa is without changes. Intestinal lumen contains large amounts of mucus. What is the most likely diagnosis in this case?

- A. Irritable bowel syndrome
- B. Crohn's disease (regional enteritis)
- C. Nonspecific ulcerative colitis
- D. Acute mesenteric ischemia
- E. Malabsorption syndrome

35. The inpatient surgery unit has introduced the method of laparoscopic cholecystectomy into its practice. As the result the average duration of postoperative care provided to the patients could be reduced to 3.4 ± 0.8 days compared to 7.3 ± 1.1 days that were required after non-laparoscopic cholecystectomy. What method of medical statistics can confirm the statistical significance of the difference between these two estimates?

- A. Calculation of Student's confidence interval
- B. Calculation of correlation coefficient
- C. Calculation of standardized ratio
- D. Calculation of average values (measures of central tendency)
- E. Calculation of relative values

36. A 37-year-old worker during a fire ended up in the area of high CO concentration. He was delivered to a hospital in unconscious state. Objectively: the skin of his face and hands is crimson. Respiration rate is 20/min. ECG: alterations specific for hypoxic myocardium. Hourly diuresis is 40 ml. Blood test: erythrocytes - $4.5 \cdot 10^{12}/L$, Hb- 136 g/L, color index - 0.9, ESR- 3 mm/hour, carboxyhemoglobin - 5%. What criterion allows determining the severity of the patient's condition?

- A. Carboxyhemoglobin concentration
- B. Respiratory disorders
- C. ECG results
- D. Extent of trophic disorders
- E. Development of chronic renal failure

37. The right arm of a newborn is stretched along the torso with all its joints extended; the shoulder is rotated inwards, while the forearm is pronated, the hand is in the position of palmar flexion. Spontaneous movements are absent in the shoulder and elbow joints, passive movements are painless. What is the most likely diagnosis?

- A. Duchenne-Erb palsy, superior proximal type
- B. Dejerine-Clumpke palsy, inferior distal type
- C. Total obstetric palsy
- D. Osteomyelitis of the right humerus
- E. Poliomyelitis

38. In April during the medical examination of various population groups, 27% of individuals presented with low working ability and rapid fatigability. The following symptoms were observed in the affected individuals: swollen friable gingiva that bleeds when pressed, hyperkeratosis follicularis not accompanied by skin dryness. These symptoms most likely result from the following pathology:

- A. C-hypovitaminosis
- B. Parodontosis
- C. A-hypovitaminosis
- D. B₁-hypovitaminosis
- E. Polyhypovitaminosis

39. A 1-year-old child with a case of URTI suddenly developed noisy respirations with difficult inspiration, intercostal retractions, and barking cough on the 2nd night after the disease onset. What is the most likely diagnosis?

- A. Stenosing laryngotracheobronchitis
- B. Acute pulmonary inflammation
- C. Bronchial asthma
- D. Acute bronchitis
- E. Acute bronchiolitis

40. A 46-year-old woman complains of severe pain attacks in the right lumbar area, which irradiate to the lower abdomen, and nausea.

This kind of pain attacks has never been detected in the patient before. Plain abdominal X-ray reveals no pathologic shadows. Ultrasound detects a hyperechogenic mass 1.5 cm in diameter, which reflects sound wave, in the enlarged right renal pelvis. What diagnosis is the most likely?

- A. Renal calculus
- B. Benign renal tumor
- C. Renal cyst
- D. Renal tuberculosis
- E. Malignant renal tumor

41. A 60-year-old woman complains of unbearable pain in her right subcostal area. She has a history of acute pancreatitis. Temperature is 38.2°C. Objectively her sclera are icteric. There are no signs of peritoneal irritation. Ortner's and Gubergrits' symptoms are positive. Urine diastase is 320 U/L. What is the most likely diagnosis?

- A. Exacerbation of chronic pancreatitis
- B. Acute cholangitis
- C. Chronic cholecystitis
- D. Acute cholecystitis
- E. Pancreatic cancer

42. A 64-year-old man complains of cough with expectoration consisting of blood-streaked mucus, dyspnea, low grade fever and general fatigue. He has been presenting with these symptoms for 3 months. He has been smoking since early adolescence. Objectively *t*^o is 37.4°C, respirations are 26/min., pulse is 82/min., rhythmic, blood pressure is 130/85 mm Hg. The right side of the thorax lags behind in the respiratory process, dull percussion sound and acute decrease of breathing activity are observed there. X-ray shows homogeneous shadow of the lung field on the right with mediastinum displacement towards the affected side. What is the most likely diagnosis?

- A. Central lung cancer
- B. Exudative pleuritis
- C. Pleuropneumonia
- D. Pulmonary tuberculosis
- E. Multiple bronchiectasis

43. For 4 days a 35-year-old man has been treated in the resuscitation unit for acute renal failure caused by compartment syndrome. The patient is disoriented. ECG shows high T waves and right ventricular extrasystoles. His central venous pressure is 159 mmH₂O; for the last 3 hours auscultation has been detecting isolated moist crackles in the lungs. Respirations are 32/min. Blood test: residual nitrogen - 62 mmol/L, K⁺ - 7.1 mmol/L, Cl⁻ - 78 mmol/L, Na⁺ - 120 mmol/L, Ht- 0.32 L/L, Hb- 100 g/L, blood creatinine - 0.9 mmol/L. In this case the most advisable would be to perform:

- A. Hemodialysis
- B. Plasmasorption
- C. Hemosorption
- D. Plasmafiltration
- E. Ultrafiltration

44. A 55-year-old woman, a cook, complains of pain in her right knee joint that has been troubling her for a month and intensifies in the evening. Objectively she is overweight, the knee joint is swollen, creaks during movement, palpation reveals localized pain. The 1st metatarsophalangeal articulation is deformed on the both feet. No changes in blood and urine are detected. What should be visible on the patient's X-ray?

- A.** Joint space narrowing, marginal osteophytes
- B.** Osteoporosis, joint space narrowing, singular usurations
- C.** Joint space narrowing, multiple usurations, subluxations
- D.** Epiphyseal erosions, bony ankylosis
- E.** Joint space narrowing, round bone defects

45. A 52-year-old woman has been suffering for 2 years from dull, occasionally exacerbating pain in her right subcostal area, occurring after eating high-fat foods, bitter taste in her mouth in the morning, constipations, and flatulence. Objectively she has excess weight, her body temperature is 36.9°C ; there is a coating on the root of her tongue; the abdomen is moderately distended and painful in the area of gallbladder projection. What examination would be the most helpful for diagnosis-making?

- A.** Ultrasound
- B.** Duodenal intubation
- C.** Cholecystography
- D.** Duodenoscopy
- E.** Liver scanning

46. A 57-year-old woman complains of weakness, dyspnea, loss of appetite, and liquid feces. She has been suffering from this condition for 2 years. Objectively she presents with pale skin, subicteric sclera, and bright-red fissured tongue. Lymph nodes are not enlarged. Pulse - 100/min. BP- 105/70 mm Hg. Liver +3 cm, the spleen cannot be palpated. Blood test: erythrocytes - $1.2 \cdot 10^{12}/\text{L}$, Hb- 56 g/L, color index - 1.4, macrocytes, leukocytes - $2,5 \cdot 10^9/\text{L}$, eosinophils - 1%, juvenile - 1%, metamyelocytes - 1%, band neutrophils - 8%, segmented neutrophils - 47%, lymphocytes - 38%, monocytes - 4%, reticulocytes - 0.1%, platelets - $100 \cdot 10^9/\text{L}$, ESR- 30 mm/hour, indirect bilirubin - 26 mmol/L. What changes can be expected in the bone marrow puncture material?

- A.** Prevalence of megaloblasts
- B.** Increased number of sideroblasts
- C.** Erythroid hyperplasia
- D.** Presence of blast cells
- E.** Prevalence of lymphoid tissue

47. A 45-year-old woman complains of paroxysmal intolerable facial pain on the left with attacks that last for 1-2 minutes. Attacks are provoked by chewing. The disease onset was two month ago after overexposure to cold. Objectively: pain at the exit points of the trigeminal nerve on the left. Touching near the wing of nose on the left induces new pain attack

with tonic spasm of the facial muscles. What is the most likely diagnosis among those listed?

- A.** Trigeminal neuralgia
- B.** Glossopharyngeal neuralgia
- C.** Temporomandibular joint arthritis
- D.** Facial migraine
- E.** Maxillary sinusitis

48. A 10-year-old boy with symptoms of arthritis and myocarditis was delivered into a hospital. Based on clinical examination the preliminary diagnosis of juvenile rheumatoid arthritis was made. What symptom is the most contributive for the diagnostics of this disease?

- A.** Reduced mobility of the joints in the morning
- B.** Regional hyperemia of the joints
- C.** Affection of the large joints
- D.** Enlarged heart
- E.** Increased heart rate

49. A 25-year-old patient was delivered to an infectious diseases unit on the 3rd day of illness with complaints of headache, pain in lumbar spine and gastrocnemius muscles, high fever, chill. Objectively: condition of moderate severity. Scleras are icteric. Pharynx is hyperemic. Tongue is dry with dry brown coating. Abdomen is distended. Liver is enlarged by 2 cm. Spleen is not enlarged. Palpation of muscles, especially gastrocnemius muscles, is painful. Urine is dark in colour. Stool is normal in colour. The most likely diagnosis is:

- A.** Leptospirosis
- B.** Viral hepatitis type A
- C.** Malaria
- D.** Infectious mononucleosis
- E.** Yersiniosis

50. A 28-year-old woman complains of skin hemorrhages after minor traumas and spontaneous appearance of hemorrhages on the front of her torso and extremities. On examination: the skin is variegated (old and new hemorrhages), bleeding gums. Blood platelets - $20 \cdot 10^9/\text{L}$; in the bone marrow there is increased number of megakaryocytes and no platelet production. Treatment with steroid hormones was effective. What is the likely diagnosis?

- A.** Idiopathic thrombocytopenic purpura
- B.** Hemophilia
- C.** Rendu-Osler-Weber disease (Hereditary hemorrhagic telangiectasia)
- D.** Disseminated intravascular coagulation
- E.** Acute vascular purpura

51. A 7-year-old boy has been an inpatient for 1.5 months. He had been delivered to the hospital with complaints of edemas all over his body, low urine output, and headache. Clinical urinalysis: proteins - 7.1 g/L, leukocytes - 1-2 in the vision field, erythrocytes - 3-4 in the vision field. During the course of treatment the edemas gradually dissipated, headache abated, diuresis normalized. Daily urine proteins - 3 g/L. Biochemical blood test: total protein - 43.2 g/L,

urea - 5.2 mmol/L, cholesterol - 9.2 mmol/L. What glomerulonephritis syndrome is the most likely to be present in the patient?

- A. Nephrotic
- B. Nephritic
- C. Isolated urinary
- D. Hematuric
- E. Mixed

52. The mother of a 3-month-old child came to a family doctor with complaints of her child being physically underdeveloped and suffering from cough attacks and dyspnea. Anamnesis: the child is the result of the second full-term pregnancy with the risk of miscarriage (the first child died of pulmonary pathology at the age of 4 months, according to the mother). Body mass at birth is 2500 g. Cough attacks were observed from the first days of life, twice the child was treated for bronchitis. Considering the severity of the child's condition the doctor made the referral for hospitalization. What diagnosis was most likely stated in the referral?

- A. Mucoviscidosis (Cystic fibrosis)
- B. Acute obstructive bronchitis
- C. Recurrent obstructive bronchitis
- D. Pertussis
- E. Acute obstructive pneumonia

53. A 10-year-old girl complains of stomachache that appears and intensifies after she eats rough or spicy food, sour eructation, heartburn, frequent constipations, headaches, irritability. She has been presenting with these signs for 12 months. Her meals are irregular and consist of dry food. Objectively her diet is sufficient in calories. The tongue is moist with white coating near the root. The abdomen is soft and painful in the epigastrium. What method would be optimal for diagnosis-making in this case?

- A. Esophagogastroduodenoscopy
- B. Intragastric pH-metry
- C. Fractional gastric analysis (Fractional test meals)
- D. Phase-contrast X-ray imaging
- E. Biochemical blood test

54. A 23-year-old patient had taken 1 g of aspirin to treat acute respiratory infection. After that he developed an asthmatic fit with labored expiration that was arrested by introduction of aminophylline. The patient's medical history is not burdened with allergies. The patient has undergone two surgeries for nasal polyposis in the past. What diagnosis is most likely?

- A. Aspirin-induced asthma
- B. Atopic bronchial asthma
- C. Infectious allergic bronchial asthma
- D. Exercise-induced asthma
- E. Symptomatic bronchospasm

55. A 50-year-old patient was delivered to a hospital with complaints of blood traces in urine. Urination is painless and undisturbed. Macrohematuria had been observed for 3 days. Objectively: kidneys cannot be palpated,

suprapubic area is without alterations, external genitalia are non-pathologic. On rectal investigation: prostate is not enlarged, painless, has normal structure. Cystoscopy revealed no alterations. What is the most likely diagnosis?

- A. Renal carcinoma
- B. Bladder tuberculosis
- C. Varicocele
- D. Dystopic kidney
- E. Necrotic papillitis

56. A 36-year-old man has been complaining of marked weakness, low appetite, and nausea for the last year, year and a half. Within the last year he has lost 10 kg of body mass. The skin is darkened, especially on his face, neck, and arms. Skin folds and nipples are hyperpigmented, there are pigment spots on the patient's inner thighs. Pulse is 60/min., blood pressure is 80/50 mm Hg. What is the provisional diagnosis?

- A. Adrenal insufficiency
- B. Diabetes mellitus
- C. Chronic gastritis
- D. Hemochromatosis
- E. Cholestatic hepatitis

57. A 5-year-old child that contacts with viral hepatitis in the kindergarten presents with increased body temperature up to 38°C, weakness, low appetite, single case of vomiting, dull pain in the subcostal area on the right. The child is provisionally diagnosed with viral hepatitis. What examination would be the most informative for diagnosis confirmation?

- A. ALT activity in blood
- B. Urine analysis for bile pigments
- C. Feces analysis for stercobilin
- D. Blood test for bilirubin
- E. Thymol turbidity test

58. A patient with trauma of the lower third of the forearm volar surface caused by a glass shard came to a first-aid center. Objectively: flexion of the IV and V fingers is impaired, sensitivity of the inner dorsal and palmar surfaces of the hand and IV finger is decreased. What nerve is damaged?

- A. Ulnar
- B. Radial
- C. Median
- D. Musculocutaneous
- E. Axillary

59. A man diagnosed with closed-angle glaucoma, grade IIa, of the right eye is registered for regular medical check-ups. In the evening an acute glaucoma attack occurred in his right eye; an ambulance was called. What emergency aid would be optimal in this case?

- A. Pilocarpine, Diacarb (Acetazolamide), lytic mixture
- B. Atropine eye drops
- C. Antibiotic eye drops, broad-spectrum
- D. Sulfacetamide sodium eye drops
- E. Dexamethasone eye drops

60. A 58-year-old patient complains of pain in the lower left extremity, which aggravates during walking, and sensation of cold and numbness in the both feet. The patient has been suffering from this condition for 6 years. Objectively: the skin is pale and dry, with hyperkeratosis. On the left shin hair is scarce. Pulse cannot be detected over the pedal and popliteal arteries and is weakened over the femoral artery. On the right limb pulsation of the popliteal artery is retained. What is the most likely diagnosis?

- A. Atherosclerosis obliterans of the lower extremities
- B. Obliterating endarteritis
- C. Femoral artery thrombosis
- D. Raynaud's disease
- E. Buerger's disease (thromboangiitis obliterans)

61. A 22-year-old woman, gravida 1, para 0 arrived with complaints of sharply painful contractions that occur every 4-5 minutes and last for 25-30 seconds. Amniotic fluid did not burst. The fetus is in transverse lie, fetal heartbeats are not affected. Contraction ring is acutely painful, located obliquely at the umbilicus. What is the most likely diagnosis?

- A. Impending uterine rupture
- B. Uterine tetany
- C. Excessive uterine activity during labor
- D. Discoordinated labor
- E. Uterine rupture

62. During regular check-up the doctor examines a young woman, a student, with height of 162 cm and weight of 59 kg. She complains that in the evening she becomes unable to see clearly the objects around her. Objectively her skin is dry, presents with hyperkeratosis. Her daily ration has the following vitamin content: vitamin A - 0.5 mg, vitamin B₁ - 2.0 mg, vitamin B₂ - 2.5 mg, vitamin B₆ - 2 mg, vitamin C - 70 mg. Make the diagnosis:

- A. A-hypovitaminosis
- B. B₁-hypovitaminosis
- C. B₂-hypovitaminosis
- D. B₆-hypovitaminosis
- E. C-hypovitaminosis

63. An infant is 2.5 months old. The onset of the disease was gradual, the child had normal body temperature but presented with slight cough. Within a week the cough intensified, especially at night; on the 12th day the child developed cough fits occurring up to 20 times per day and followed by vomiting. There was one instance of respiratory arrest. Make the diagnosis:

- A. Pertussis
- B. Parainfluenza
- C. Congenital stridor
- D. Respiratory syncytial infection
- E. Adenovirus infection

64. A man works in casting of nonferrous metals and alloys for 12 years. In the air of working area there was registered high content of heavy metals, carbon monoxide, and nitrogen. During periodic health examination the patient presents with asthenovegetative syndrome, sharp pains in the stomach, constipations, pain in the hepatic area. In urine: aminolevulinic acid and coproporphyrin are detected. In blood: reticulocytosis, low hemoglobin level. Such intoxication is caused by:

- A. Lead and lead salts
- B. Tin
- C. Carbon monoxide
- D. Nitric oxide
- E. Zinc

65. Due to introduction of a new treatment method, average duration of therapy in the experimental group was 12.3 ± 0.2 days compared to 15.4 ± 0.4 days in the control group that was treated by the old method. What calculations should be made to estimate the statistical significance of the difference in the results?

- A. T-test (Student's t-distribution)
- B. Sign test (Z-test)
- C. Matching factor (chi-squared test)
- D. Wilcoxon T-test
- E. Kolmogorov-Smirnov test

66. Establishments participating in medical examinations include: medical and preventive treatment facilities, hygiene and preventive treatment facilities, sociomedical expert committees, Ministry of Defence medical committees, Ministry of Domestic Affairs medical committees, forensic medicine agency, etc. Specify what service deals with sociomedical assessment of temporary disability:

- A. Medical and preventive treatment facilities
- B. Hygiene and preventive treatment facilities
- C. Sociomedical expert committees
- D. Ministry of Defence medical committees
- E. Ministry of Domestic Affairs medical committees

67. A 14-year-old boy presents with moderate bronchial asthma in its exacerbation period. What drug should be prescribed to stop an acute attack of expiratory dyspnea?

- A. Salbutamol
- B. Cromolyn sodium (Cromoglicic acid)
- C. Dexamethasone
- D. Lasolvan (Ambroxol)
- E. Strophanthine (cardiac glycosides)

68. A newborn with gestational age of 31 weeks presents with hypotonia and depressed consciousness. Hematocrit is 35%, general

cerebrospinal fluid analysis shows increased content of erythrocytes and protein, and low glucose. These data correspond with the clinical presentation of:

- A. Intracranial hemorrhage
- B. Meningitis
- C. Sepsis
- D. Anemia
- E. Prenatal infection

69. A 16-year-old girl has primary amenorrhea, no pubic hair growth, normally developed mammary glands; her genotype is 46 XY; uterus and vagina are absent. What is your diagnosis?

- A. Testicular feminization syndrome
- B. Mayer-Rokitansky-Kuster-Hauser syndrome
- C. Cushing syndrome
- D. Sheehan syndrome
- E. Cushing disease

70. 6 hours ago the waters of a 30-year-old gravida 1, para 0, burst; her preliminary period was pathologic and lasted for over 2 days; the term of pregnancy is 39 weeks. No labor activity is observed. Fetal head presents above the pelvic inlet. Fetal heartbeats are 142/min., clear and rhythmic. On vaginal examination the uterine cervix is not dilated. What further tactics should the doctor choose?

- A. Perform cesarean section
- B. Induce cervical dilation with prostaglandins
- C. Stimulate the labor with oxytocin
- D. Wait for the onset of spontaneous labor
- E. Prolong the pregnancy, while providing antibacterial treatment

71. Mother of an 8-year-old girl complains that the child is too short and has excessive body weight. Objectively: obesity with fat deposits on the torso and face (round moon-like face), acne, striae on the thighs and lower abdomen, hirsutism. What hormone can cause such symptoms, when in excess?

- A. Cortisol
- B. Thyroxin
- C. Testosterone
- D. Insulin
- E. Glucagon

72. A 9-year-old girl complains of fever up to 38.5°C , headache, inertness, weakness, loss of appetite, stomachache, and frequent painful urination. Provisional diagnosis of acute pyelonephritis is made. Clinical urine analysis: specific gravity - 1016, no protein, leukocytes - 10-15 in the vision field. What investigation method can verify the diagnosis of urinary tract infection?

- A. Bacteriological inoculation of urine
- B. Rehberg test (creatinine clearance test)
- C. Zymnitsky test (density measurement of daily diuresis)
- D. Complete blood count
- E. Clinical urine analyses, dynamic testing

73. A newborn has Apgar score of 9. When

should the infant be put to the breast?

- A. In the delivery room
- B. After 12 hours
- C. After 2 hours
- D. On the 2nd day
- E. On the 3rd day

74. During assessment of work conditions at the factory manufacturing mercury thermometers, the content of mercury vapors in the air of the working area is revealed to exceed the maximum concentration limit. Specify the main pathway of human body exposure to mercury:

- A. Respiratory organs
- B. Intact skin
- C. Damaged skin
- D. Gastrointestinal tract
- E. Mucous tunics

75. In the process of hiring, a prospective employee has undergone preventive medical examination and was declared fit to work in this manufacturing environment. What type of preventive medical examination was it?

- A. Preliminary
- B. Scheduled
- C. Periodical
- D. Specific
- E. Comprehensive

76. A 47-year-old woman came to the admission room with complaints of general weakness, dizziness, vomiting with blood clots. Condition onset was 3 hours ago. The patient has no preceding illnesses. Blood pressure is 90/60 mm Hg, pulse is 106/min., of poor volume. The abdomen is soft, with mild tenderness in the epigastrium. Blood test: erythrocytes - $2.1 \cdot 10^{12}/\text{L}$, Hb- 70 g/L, hematocrit - 28%. What tactics should the doctor on duty choose?

- A. Consult the surgeon
- B. Refer the patient to the family doctor
- C. Give spasmolytics
- D. Perform gastric lavage
- E. Make an appointment for colonoscopy

77. A 23-year-old woman came the the gynecologist with complaints of blood smears from her genital tracts that have been observed for a long time. Her menstruation has been delayed for 8 weeks. Examination shows the uterine body to be enlarged up to 14 weeks of pregnancy. US detected a vesicular mole. What tactics should the doctor choose?

- A. Curettage of the uterine cavity
- B. Hormonal treatment
- C. Hemostatic treatment
- D. Supravaginal uterine amputation
- E. Uterectomy

78. A 52-year-old patient complains of pain in the right part of her chest, dyspnea, cough with large amounts of foamy sputum emitting foul smell and resembling "meat slops". Objectively: the patient's condition is grave, cyanosis is observed, breathing rate is 31/min.,

percussion sound above the right lung is shortened, auscultation revealed various moist rales (crackles). What is the most likely diagnosis?

- A. Lung gangrene
- B. Lung abscess
- C. Empyema of pleura
- D. Multiple bronchiectasis
- E. Chronic pneumonia

79. A man complains of sore throat on the left, pain in his left ear, t° up to $39^{\circ}C$, and nasal sound of his voice. Disease onset was 5 days ago. Marked trismus and increased salivation are observed. The head tilts to the left shoulder. Left side of the soft palate presents with swelling, hyperemia, and infiltration. Retromandibular lymph nodes on the left are acutely painful on palpation. Otoscopy results are normal. Make the diagnosis:

- A. Left-sided peritonsillar abscess
- B. Retropharyngeal abscess
- C. Parapharyngeal phlegmon
- D. Peritonsillitis on the left
- E. Cervical phlegmon on the left

80. A patient has the second and third degree burns of the 15% of the body surface. On the 20th day after the trauma the patient presents with sharp increase of body temperature, general weakness, rapid vesicular respiration; facial features are sharpened, BP is 90/50 mm Hg, heart rate is 112/min. What complication is it?

- A. Sepsis
- B. Pneumonia
- C. Acute intoxication
- D. Purulent bronchitis
- E. Anaerobic infection

81. A patient in the state of clinical death is being resuscitated through mouth-to-mouth artificial pulmonary ventilation and external cardiac massage. A doctor noticed that air does not flow into the patient's airways and his head and torso are positioned at the same level. Why is artificial respiration ineffective in the given case?

- A. Tongue retraction
- B. Low breathing volume
- C. External cardiac massage
- D. Probe is absent from the stomach
- E. The patient's mouth is too small

82. An employee has been sick for 4 months, further treatment is necessary, the patient is unable to work. Who is authorized to provide further disability examination of this patient?

- A. Sociomedical expert committee
- B. Medical consultative board
- C. Physician in charge and the head of the department
- D. Chief physician of a medical facility
- E. Deputy chief responsible for disability examination

83. A population of a small town often presents with registered cases of juvenile cardiomyopathy, atherosclerosis, hypertension, endocrinopathy, chronic dermatitis, and arthralgia - signs of Keshan disease. What is the most likely cause of this pathology?

- A. Selenium deficiency in the environment
- B. Excessive iron in the environment
- C. Strontium deficiency in the environment
- D. Excessive zinc in the environment
- E. Excessive manganese in the environment

84. In 2 hours after a traffic accident a 28-year-old man in grave condition was delivered to a hospital. The patient complains of abdominal pain. He received a blow to the abdomen with the steering wheel. Objective examination revealed the following: the abdomen does not participate in respiration, is tense and acutely painful on palpation; abdominal guarding is present, peritoneal irritation signs are positive, hepatic dullness is absent. BP is 90/60 mm Hg, heart rate is 120/min. What further treatment tactics should be chosen?

- A. Laparotomy
- B. Laparoscopy
- C. Cold to the abdomen
- D. Abdominal X-ray
- E. Laparocentesis

85. A 48-year-old woman was arrived to the surgical unit with wounds in her thigh. On examination the wound surface has dirty-gray coating with unpleasant sweet smell. Wound content resembles raspberry jelly. Skin tissues around the wound are glossy and turgid. Palpation reveals moderate crepitation in the tissues. What microflora is the most likely to cause such inflammation?

- A. Anaerobic clostridial
- B. Anaerobic non-clostridial
- C. Streptococci
- D. Staphylococci
- E. Blue pus bacillus

86. The gynecology unit received a patient with uterine bleeding that started 6 hours after induced abortion at the term of 11-12 weeks. Objectively the skin is pale, pulse is 100/min., blood pressure is 100/70 mm Hg. On vaginal examination the uterus is painless, its enlargement corresponds to the 10th week of pregnancy; uterine cervix is dilated enough to let in one finger, there are fragments of the fertilized ovum. What actions should be taken next:

- A. Urgent repeated curettage of the uterine cavity
- B. Uterotonic drugs
- C. Treatment for acute anemia
- D. Antibacterial agents
- E. Prescribe rest and continue to monitor the patient's condition

87. A woman came to the general practitioner with complaints of fatigability, significant weight loss, weakness, and loss of appetite. She has been presenting with amenorrhea for the last

8 month. One year ago she gave birth to a live full-term child. Blood loss during delivery was 2 liters. The woman received blood transfusion and blood components. What is the most likely diagnosis?

- A. Sheehan's syndrome (postpartum hypopituitarism)
- B. Stein-Leventhal syndrome (polycystic ovary)
- C. Turner's syndrome
- D. Homologous blood syndrome
- E. Somatoform autonomic dysfunction

88. To assess the effectiveness of medical technologies and determine the power and direction of their effect on the public health indicators, the research was conducted to study the immunization rate of children and measles incidence rate by district. What method of statistical analysis should be applied in this case?

- A. Calculation of correlation coefficient
- B. Calculation of morbidity index among the nonvaccinated
- C. Calculation of coefficient of agreement
- D. Calculation of standardized ratio
- E. Calculation of statistical significance of the difference between two estimates

89. A 22-year-old woman complains of itching and profuse discharge from her genital tracts. The condition developed 10 days ago after a sexual contact. Bacterioscopy of a discharge sample detected trichomonads. What drug should be prescribed for treatment in this case?

- A. Metronidazole
- B. Ampicillin
- C. Erythromycin
- D. Zovirax (Acyclovir)
- E. Valcyclovir

90. A 30-year-old patient was hospitalized in an intensive care unit with a diagnosis of multiple bee stings. Skin is pale and covered with cold sweat. Pulse can be palpated only at the carotid arteries and is 110/min.; breathing rate is 24/min., rhythmical, weakened. What drug must be administered immediately?

- A. Epinephrine hydrochloride
- B. Prednisolone
- C. Norepinephrine hydrochloride
- D. Dopamine
- E. Tavegil (Clemastine)

91. A 46-year-old woman has been hospitalized with open fracture of the left thigh in its middle third. She underwent the surgery - fixation with extraosseous osteosynthesis plates. On the 4th day after the surgery she developed pain in the wound, body temperature rose over 39°C. What measures should be taken in this case?

- A. Undo the sutures, drain the wound, and prescribe antibiotics
- B. Prescribe broad spectrum antibiotics and hormonal agents
- C. Administer antibiotics intraosseously and hypothermia locally
- D. Inject antibiotics into the area surrounding the wound, prescribe spasmolytics and analgesics
- E. Remove the fixation, prescribe sulfanilamides

92. A woman with blood group B(III) Rh(+) gave birth to a full-term healthy boy. Examination on the 3rd day of the infant's life shows him to have icteric tint to his skin. The child has no problems with suckling, sleep is nondisturbed. The abdomen is soft, the liver protrudes by 2 cm from under the costal margin. Complete blood count: hemoglobin - 200 g/L, erythrocytes - $5.5 \cdot 10^{12}/L$, total bilirubin - 62 $\mu\text{mol}/L$, indirect bilirubin - 52 $\mu\text{mol}/L$. What condition can be suspected?

- A. Physiologic jaundice
- B. Congenital hepatitis
- C. Hemolytic disease of the newborn due to Rh incompatibility
- D. Biliary atresia
- E. Hemolytic disease of the newborn due to ABO incompatibility

93. A 45-year-old man developed constricting retrosternal pain that occurs during walks at the distance of 200 m. Objectively heart rate is 80/min., BP is 160/90 mm Hg. During cardiopulmonary exercise test at 50 W there is a depression of S-T segment by 3 mm below the isoline in V3-V4. What is the provisional diagnosis?

- A. Exertional angina pectoris, functional class III
- B. Exertional angina pectoris, functional class IV
- C. Exertional angina pectoris, functional class II
- D. Somatoform autonomic dysfunction, hypertension type
- E. Alcoholic myocardiodystrophy

94. A multigravida on the 38th week of her pregnancy complains of increased BP up to 140/90 mm Hg, edema of the shins for 2 weeks. In the last month she gained 3.5 kg of weight. Urine analysis: protein - 0.033 g/L. Make the diagnosis:

- A. Mild preeclampsia
- B. Moderate preeclampsia
- C. Pregnancy hypertension
- D. Severe preeclampsia
- E. Pregnancy edema

95. For the last 15 years a 48-year-old patient has been working at the factory producing synthetic resins. Lately he has been complaining of significant general fatigue, headaches, frequent urination (predominantly during the day), red color of urine. What complication of benzene nitrocompounds poisoning can be suspected?

- A. Malignant tumor of the urinary bladder
- B. Chronic cystitis
- C. Chronic prostatitis
- D. Acute glomerulonephritis
- E. Chronic pyelonephritis

96. A 44-year-old patient with postinfarction cardiosclerosis presents with frequent heart rate disorders and lower extremity edema. Objectively: Ps- 95/min., irregular, 10-12 extrasystoles per minute. BP- 135/90 mm Hg. The 1st heart sound at the apex is weakened. Pulmonary respiration is rough. The liver is enlarged +2 cm. ECG: irregular sinus rhythm, heart rate - 95/min., frequent polytopic ventricular extrasystoles. What antiarrhythmic drug is advisable in this case for treatment and prevention of extrasystole?

- A. Amiodarone
- B. Lidocaine
- C. Mexiletine
- D. Quinidine
- E. Novocainamide (Procainamide)

97. A 60-year-old woman started feeling weakness, vertigo, rapid fatigability during the last year. Recently she has developed dyspnea and paresthesia observed. Objectively: skin and mucous membranes are pale and icteric. Lingual papillae are smoothed out. Liver and spleen are at the edge of costal arch. Blood test: Hb- 70 g/L, erythrocytes - $1.7 \cdot 10^{12}/L$, blood color index - 1.2, macrocytes. What drug can be prescribed on pathogenetic grounds?

- A. Vitamin B_{12}
- B. Vitamin B_6
- C. Ascorbic acid
- D. Iron preparations
- E. Vitamin B_1

98. After excessive consumption of fatty food a 60-year-old woman suddenly developed pain in her right subcostal area, nausea, bile vomiting, sharp bitter taste in her mouth. In 2 days she developed jaundice, her urine darkened. Objectively: sclera and skin are icteric, the abdomen is distended, the liver is enlarged by 3 cm, soft and painful on palpation, Ortner's, Murphy's, Kehr's, Zakharyin's, Mayo-Robson's signs are positive. What diagnostic technique should be used in the first place to confirm the diagnosis?

- A. Ultrasound of the gallbladder and bile duct
- B. Fibrogastroduodenoscopy
- C. Abdominal X-ray
- D. Radionuclide scanning of the liver and gallbladder
- E. Laparoscopy

99. The objective of a statistical research was to find out to what extent the population peruses the available medical services. For this purpose 300 residents of the area were interviewed. Information was collected by means of a special questionnaire. What method of collecting information was used by the researchers?

- A. Anamnestic (history-taking)
- B. Immediate registration
- C. Immediate examination
- D. Doing extracts
- E. -

100. A 30-year-old woman complains of increased body weight and problems with physical exertion. Her parents are of increased body weight as well; typical meals in their family are high in fats and carbohydrates. Objectively her blood pressure is 135/80 mm Hg, pulse is 89/min., weight is 87 kg, height is 165 cm. The patient's skin is clear, with even distribution of subcutaneous fat; the thyroid gland is not enlarged; there are no menstrual cycle disturbances. What obesity prevention methods would be the most advisable in this case?

- A. Dietary treatment, graduated exercise
- B. Intensive training regimen
- C. Gastroplasty or gastrojejunal shunt
- D. Inhibitors of gastrointestinal lipases
- E. Anorectic drugs

101. A 43-year-old woman complains of pain in the lumbar area, which irradiates to her left leg and aggravates on movement, and sensation of numbness in this leg. Objectively palpation of her shin and thigh is painful, there are painful stretch symptoms of on the left and gastrocnemius cramps. There is no sensory loss or weakening of reflex responses. Make the diagnosis:

- A. Vertebrogenous lumbar ischialgia on the left
- B. Vertebrogenous radicular syndrome of L5-S1 on the left
- C. Left-sided coxitis
- D. Endarteritis of the lower extremities
- E. Spinal stroke

102. A 3-day-old infant with hyperbilirubinemia (428 $\mu\text{mol/L}$) developed disturbances manifesting as periodical excitations and convulsions against the background of inertness, hypotension, hypodynamia, and inhibition of unconditioned reflexes, convergent strabismus, rotational nystagmus, and setting-sun eye phenomenon. What is the most likely cause of such symptoms?

- A. Bilirubin encephalopathy
- B. Craniocerebral injury
- C. Brain tumor
- D. Hydrocephalus
- E. Infantile cerebral paralysis

103. A woman undergoing in-patient treatment for viral hepatitis type B developed headache, nausea, recurrent vomiting, memory lapses, flapping tremor of her hands, rapid pulse. Sweet smell from the mouth is detected. Body temperature is 37.6°C , heart rate is 89/min. What complication developed in the patient?

- A. Acute liver failure
- B. Ischemic stroke
- C. Gastrointestinal hemorrhage
- D. Hypoglycemic shock
- E. Meningoencephalitis

104. A patient with chronic pancreatitis complains of diarrhea occurring up to 5 times per day (no blood traces), loss of body weight, abdominal distention, dryness of skin, loss of hair, thirst, bleeding gums, convulsions. Complete blood count: leukocytes - $5.8 \cdot 10^9/L$; Hb- 86 g/L; ESR- 15 mm/g; Blood protein test: total protein - 48 g/L; albumins - 28 g/L. What indicators of coprological analysis would accompany this syndrom?

- A. Steatorrhea, creatorrhea
- B. Large amount of mucus, amyloorrhea
- C. Large amount of starch grains and cellulose
- D. Gas bubbles, acid reaction
- E. Large numbers of iodophilous microbes

105. A 43-year-old woman complains of persistent stomachache with recurrent pain attacks, nausea, repeated vomiting with stagnant bowel content, abdominal distension, and flatulence. She has been presenting with these signs for 7 hours. Pulse is 116/min. The tongue is dry and brown. The abdomen is symmetrically distended, soft, painful. Percussion reveals tympanitis. On auscultation there are bowel sounds with metallic overtone, splashing, and dripping. Make the diagnosis:

- A. Acute intestinal obstruction
- B. Acute necrotizing pancreatitis
- C. Acute destructive cholecystitis
- D. Acute erosive gastritis
- E. Acute nonspecific colitis

106. After overexposure to cold a 45-year-old woman developed acute pain in her suprapubic and lumbar areas during urination, sharp pains at the end of urination, false urges to urinate. Urine is turbid with blood streaks. The doctor suspects urinary tract infection. What results of laboratory analysis would be the most indicative of such infection?

- A. Leukocyturia, gross hematuria
- B. Gross hematuria
- C. Increased blood creatinine and blood urea
- D. Daily proteinuria under 3.0
- E. Daily proteinuria over 3.0

107. A 15-year-old adolescent girl came the the gynecologist with complaints of painful menstruations that are accompanied by nausea, vomiting, and dizziness. Her menarche was at 12. Menstruations became painful since she was 14, remain regular. What treatment should be prescribed in this case?

- A. Analgesics, antispasmodics, antiprostaglandine therapy
- B. Antiinflammatory treatment only
- C. Antihemorrhagic agents
- D. Antiandrogen therapy
- E. Vitamin supplements

108. A 38-year-old patient has been delivered by an ambulance to a surgical department with complaints of general weakness, indisposition, black stool. On examination the patient is pale, there are dotted hemorrhages on the skin of his torso and extremities. On digital investigation there are black feces on the glove. Blood test: Hb- 108 g/L, thrombocytopenia. Anamnesis states that similar condition was observed 1 year ago. Make the diagnosis:

- A. Thrombocytopenic purpura
- B. Hemophilia
- C. Bleeding from an ulcer
- D. Rectal tumor
- E. Nonspecific ulcerative colitis

109. A 35-year-old patient developed an epileptic attack with tonoclonic spasms that lasted for 3 minutes. After the attack the patient fell asleep but in 5 minutes the second attack occurred. The first step of emergency aid would be to:

- A. Ensure patency of airways
- B. Take blood from the vein for analysis
- C. Introduce diazepam intravenously
- D. Prescribe antiepileptic drugs
- E. Administer chloral hydrate via enema

110. A young woman suffering from seborrhea oleosa has numerous light-brown and white spots on the skin of her torso and shoulders. The spots have clear margins, branny desquamation, no itching. What provisional diagnosis can be made?

- A. Pityriasis versicolor
- B. Torso dermatophytosis
- C. Seborrheic dermatitis
- D. Pityriasis rosea
- E. Vitiligo

111. A patient is 28 years old. He has been suffering from mental disorder since he was 22. His current condition has changed acutely: for 3 days the patient has been refusing to leave his home. He claims that there is a "telepathy" occurring between him and other people, through which he receives "thoughts of strangers" and transmits his own thoughts for everyone to hear. He thinks his thoughts and actions are manipulated through this "telepathy". Make the preliminary diagnosis:

- A. Paranoid schizophrenia
- B. Depressive episode
- C. Catatonic episode
- D. Organic delirium
- E. Acute reaction to stress

112. A 3-year-old child presents with sharp deterioration of his general condition. He has a history of purulent otitis. His temperature is now $38.5^{\circ}C$. The left leg is pressed to the torso, active movements are absent, the lower third of the thigh and knee joint are thickened, hyperemic, with localized fever. Axial load leads to acute discomfort of the patient. What is the most likely diagnosis?

- A. Epiphyseal osteomyelitis on the left
- B. Left hip fracture
- C. Rheumatoid arthritis
- D. Osteogenic sarcoma
- E. Hygroma of the knee

113. A 19-year-old student was urgently hospitalized due to marked dyspnea and chest pain on the left. Her body temperature is 38.8°C. She has been presenting with these signs for 3 days. Respiratory rate is 42/min., shallow. Percussion sound is dull to the left from the center of the scapula, no respiration can be auscultated. The left heart border is displaced outwards by 3 cm. Embryocardia and heart rate of 110/min are observed. Palpation of the right subcostal area is painful. What urgent measures should be taken in this case?

- A. Urgent thoracocentesis
- B. Prescription of penicillin antibiotics
- C. Administration of furosemide
- D. Administration of cardiac glycosides
- E. Referral into thoracic surgery unit

114. A 20-year-old woman, gravida 2, para 1 has been in labor for 4 hours. Her condition is satisfactory. Moderately painful contractions occur every 3 minutes and last for 35-40 seconds. The waters have not burst yet. The fetus is in longitudinal position. Fetal heartbeats are 136/min., clear and rhythmic. Major segment of the fetal head is engaged to the pelvic inlet. Vaginal examination shows smooth cervix of 6cm, amniotic sac is intact, sagittal suture is in the left oblique diameter, occipital fontanel is on the right near the symphysis pubis. What stage of the labor is it?

- A. Active phase of the first stage of normal labor
- B. Latent phase of the first stage of normal labor
- C. The second stage of normal labor
- D. Precursors of childbirth
- E. Preliminary stage

115. A 1.5-month-old child on breastfeeding presents from birth with daily vomiting, irregular liquid foamy feces, and flatulence, which are resistant to antibacterial and probiotic therapy; no increase of body mass is observed. The child's condition improved, when breastmilk was substituted. What pathology is it?

- A. Lactase deficiency
- B. Intestinal lambliaiasis (Giardiasis)
- C. Infectious enteritis
- D. Drug-induced enteritis
- E. Functional dyspepsia

116. A 72-year-old man complains of lower extremity edema, sensation of heaviness in the right subcostal area, dyspnea in rest. For over 25 years he has been suffering from COPD. Objectively: orthopnea, jugular venous distention, diffuse cyanosis, acrocyanosis. Barrel chest is observed, on percussion there is vesiculotympanic (bandbox) resonance, sharply weakened vesicular respiration on both sides, moist crepitant crackles in the lower segments

of the lungs. Heart sounds are weakened, the II heart sound is accentuated over the pulmonary artery. The liver is +3 cm. What complicated the clinical course of COPD in this patient?

- A. Chronic pulmonary heart
- B. Pulmonary embolism
- C. Acute left ventricular failure
- D. Diffuse pneumosclerosis
- E. Community-acquired pneumonia

117. A burn victim with flame burns of the IIIA-B and IV degrees on his face, neck, and anterior surface of the thorax was brought into the admission room. The hairs in his nostrils are burnt, his labial and glossal mucosa are gray-white. The voice is hoarse; respirations are frequent and shallow; the patient has trumpet-like cough that produces soot-streaked sputum. The signs of respiratory failure were progressing, while the patient was being transported into the intensive care unit. What emergency care must be provided to this patient?

- A. Intubation of the trachea and mechanical ventilation
- B. Tracheostomy
- C. Administration of bronchial spasmolytics
- D. Administration of respiratory analeptics
- E. Inhalation of moisturized oxygen

118. A 72-year-old man with pneumonia complains of marked dyspnea, chest pain, severe cough with expectoration, t° is 39.5-40°C, no urination for a whole day. Objectively the patient is conscious. Respiratory rate is 36/min. Over the right lower pulmonary lobe percussion sound is dull; on auscultation there is bronchial respiration and numerous moist crackles. Blood pressure is 80/60 mm Hg. Heart rate is 120/min. Heart sounds are muffled, there is tachycardia. What tactics should the family doctor choose in the management of this patient?

- A. Hospitalization into intensive care unit
- B. Outpatient treatment
- C. Treatment in the day patient facility
- D. Hospitalization into pulmonology unit
- E. Hospitalization into neurology unit

119. Estimation of community health level involved analysis of a report on diseases registered among the population of district under charge (reporting form 12). What index is calculated based on this report?

- A. Prevalence
- B. Index of pathological affection
- C. Index of morbidity with temporary disability
- D. Index of hospitalized morbidity
- E. Index of basic non-epidemic morbidity

120. A 72-year-old woman suffers from diabetes mellitus type II, concomitant diseases are stage II hypertension and stage IIB heart failure. She takes metformin. Hypertensive crisis had occurred the day before, after which the patient developed extreme weakness, myalgias, thirst, dry mouth, polyuria. BP is 140/95 mm Hg, heart rate is 98/min., no edemas or smell of acetone

detected. What measures should be taken to prevent development of comatose state in the patient?

- A. Stop metformin, prescribe short-acting insulin
- B. Double the dosage of metformin
- C. Apply hypotonic solution of sodium chloride
- D. Additionally prescribe long-acting insulin
- E. Prescribe glibenclamide

121. The body of a 24-year-old woman with probable signs of poisoning has been found on the street. Forensic medical examination was requested by an investigator during examination of the site and the body. According to the Criminal Procedure Code currently in force in Ukraine, forensic medical examination is required when it is necessary to determine the:

- A. Cause of death
- B. Manner of death
- C. Time of death
- D. Mode of death
- E. Mechanism of death

122. It is the 3rd day after the normal term labor; the infant is rooming-in with the mother and is on breastfeeding. Objectively: the mother's general condition is satisfactory. Temperature is 36.4°C , heart rate is 80/min., BP is 120/80 mm Hg. Mammary glands are soft and painless; lactation is moderate, unrestricted milk flow. The uterus is dense, the uterine fundus is located by 3 fingers width below the navel. Lochia are sanguino-serous, moderate in volume. Assess the dynamics of uterine involution:

- A. Physiological involution
- B. Subinvolution
- C. Lochiometra
- D. Pathologic involution
- E. Hematometra

123. A 27-year-old man was hospitalized in severe condition 50 minutes after receiving a penetrating wound to the left side of the chest. Objectively the patient is in a stupor, his skin is pale and acrocyanotic. Pulse is 120/min., of poor volume, weak. Blood pressure is 80/40 mm Hg. Heart sounds are muffled, cardiac borders are markedly expanded. In the III intercostal area along the parasternal line on the left there is a stab-incised wound. Plain chest X-ray shows enlarged heart shadow with smoothed out waist of the heart, there is hemothorax on the left to the 5th rib. What contributes the most to the severity of the patient's condition?

- A. Cardiac tamponade
- B. Acute heart failure
- C. Cardiac rhythm disturbance
- D. Blood loss
- E. Hemothorax and acute respiratory failure

124. A 59-year-old patient suffering from hypertension was delivered to the hospital with complaints of acute headache, nausea, recurrent vomiting. On examination she presents with acute meningeal symptom

complex. BP is 185/105 mm Hg. What additional examination would you recommend to the patient in the first place?

- A. Lumbar puncture
- B. Ventriculopuncture
- C. Echoencephalography
- D. Rheoencephalography
- E. Electroencephalography

125. During regular examination of a 2-year-old boy, he presents with enlarged left kidney, painless on palpation. The right kidney was undetectable on palpation. Excretory urography shows no contrast on the right. Cytoscopy detected hemiatrophy of the urinary bladder trigone, the right ureteral orifice is not detected. What pathology is it?

- A. Agenesis of the right kidney
- B. Dystopia of the right kidney
- C. Hypoplasia of the right kidney
- D. Agenesis of the right ureter
- E. Ectopic right ureteral orifice

126. A 5-year-old child has body temperature risen up to febrile numbers, suffers from inertness, weakness. Examination revealed hemorrhage on the skin of limbs and torso. Enlargement of cervical and axillary lymph nodes can be detected. The liver is 4 cm below the costal arch; the spleen is 6 cm below the costal arch. Blood test: erythrocytes - $2.3 \cdot 10^{12}/\text{L}$, Hb- 60 g/L, platelets - $40 \cdot 10^9/\text{L}$, leukocytes - $32.8 \cdot 10^9/\text{L}$, eosinophiles - 1%, band neutrophiles - 1%, segmented neutrophiles - 12%, lymphocytes - 46%, monocytes - 1%, blasts - 40%, Duke's bleeding time test result is 9 min. What examination is necessary to make the diagnosis?

- A. Myelogram (bone marrow biopsy)
- B. Lymph nodes biopsy
- C. Abdominal US
- D. Detection of hepatitis markers
- E. Analysis of dynamic platelet function

127. A 36-year-old man complains of marked dyspnea and cardiac pain. He ascribes his disease to the case of influenza that he had 2 weeks ago. Objectively he leans forward when sitting. The face is swollen, cyanotic, cervical veins are swollen. Heart borders are extended on the both sides, heart sounds are muffled, heart rate = Ps = 118/min., BP is 90/60 mm Hg. Blood test: ESR is 16 mm/hour. ECG shows low voltage. X-ray shows trapezoidal cardiac silhouette and signs of pulmonary congestion. Choose the treatment tactics:

- A. Pericardial puncture (pericardiocentesis)
- B. Diuretics
- C. Antibiotics
- D. Pericardectomy
- E. Glucocorticosteroids

128. A 25-year-old patient is not married and has sexual relations with several partners. During the last 3 months he noticed small amount of mucoserous secretions produced from urethra.

Subjectively: periodical itching or burning pain in urethra. Two months ago pain in knee joint developed. Possibility of trauma or exposure to cold is denied by the patient. During the last week eye discomfort is noted - lacrimation and itching. What provisional diagnosis can be suggested?

- A. Reactive arthritis
- B. Rheumatoid arthritis
- C. Seasonal pollinosis
- D. Bacterial nonspecific urethral conjunctivitis
- E. URTI with conjunctiva and joints affected

129. A woman complains of weight gain, chills, edema, xeroderma, somnolence, difficulties with focusing. Objectively: height is 165 cm; weight is 90 kg; body proportions are of female type, t° - 35,8°C, heart rate - 58/min., BP-105/60 mm Hg. Heart sounds are weakened, bradycardia is observed. Other internal organs have no alterations. Thyroid gland cannot be palpated. Milk secretion from mammary glands is observed. Hormone test revealed increased levels of thyroid-stimulating hormone (TSH) and prolactin, and decreased level of thyroxine (T_4). What is the cause of obesity?

- A. Primary hypothyroidism
- B. Secondary hypothyroidism
- C. Prolactinoma
- D. Hypopituitarism
- E. Adiposogenital dystrophy

130. A 54-year-old patient complains of weakness, jaundice, itching skin. Disease onset was 1.5 months ago: fever up to 39°C appeared at first, with progressive jaundice developed 2 weeks later. On hospitalisation jaundice was severely progressed. Liver cannot be palpated. Gallbladder is enlarged and painless. Blood bilirubin is 190 μ mol/L (accounting mainly for direct bilirubin). Stool is acholic. What is the most likely reason for jaundice in this patient?

- A. Mechanical jaundice
- B. Hepatocellular jaundice
- C. Hemolytic jaundice
- D. Caroli syndrome
- E. Gilbert's syndrome

131. A 23-year-old man came to the surgeon with complaints of pain, redness of the skin, and swelling in the area of his proximal interphalangeal joint of the III finger on the right hand. Six days ago he pricked his finger with a wire. Objectively the III finger on the right hand is swollen, hyperemic, prominent in the projection of interphalangeal joint, sharply painful on touch and during movements. Finger mobility is reduced. Fluctuation sign is present. What diagnosis corresponds to the given clinical presentation?

- A. Articular panaritium
- B. Bone panaritium
- C. Subcutaneous panaritium
- D. Pandactylitis
- E. Finger furuncle

132. A 28-year-old woman complains of nausea, stomachache, pain in her tongue, and liquid feces. Three days ago she ate poorly salted pike caviar. Objectively her skin is pale, the tongue looks "lacquered" (bald tongue). Pulse is 100/min., with muffled heart sounds and systolic murmur over the cardiac apex. Blood pressure is 95/50 mm Hg. The liver is enlarged by 3 cm. Hemogram shows anemia, eosinophils - 18%. Oval helminth eggs were detected in feces. Make the provisional diagnosis:

- A. Diphyllbothriasis
- B. Trichinosis
- C. Teniasis
- D. Taeniarhynchosis
- E. Ascariidiasis

133. A 30-year-old woman complains of milk discharge from her breasts and no menstruation for the last 5 months. One physiologic childbirth was 4 years ago. There are no maldevelopments of mammary glands. Bimanual examination revealed diminished uterus and normal sized ovaries. MRI-scan shows no brain pathologies. Thyroid-stimulating hormone is within normal limits. Serum prolactin is high. What is the most likely diagnosis?

- A. Hyperprolactinemia
- B. Hypothyroidism
- C. Polycystic ovaries
- D. Pituitary adenoma
- E. Sheehan's syndrome (postpartum hypopituitarism)

134. A 25-year-old woman during self-examination detected a tumor in the upper external quadrant of her right mammary gland. On palpation: painless, dense, mobile growth 2 cm in diameter is detected in the mammary gland; no changes in the peripheral lymph nodes are observed. On US of the mammary glands: in the upper external quadrant of the right mammary gland there is a space-occupying lesion of increased echogenicity 21x18 mm in size. The most likely diagnosis is:

- A. Fibrous adenoma
- B. Breast cyst
- C. Diffuse mastopathy
- D. Breast cancer
- E. Mastitis

135. A 45-year-old woman underwent one year ago mastectomy followed by chemo- and radiation therapy. She now complains of dyspnea at rest and temperature up to 37,2°C. Her general condition is severe, acrocyanosis is observed. The right side of her chest practically does not participate in respiration. Percussion reveals a dull sound below the 3rd rib; auscultation detects acute weakening of the respiratory sounds. Pleural puncture on the right has yielded a large amount of hemorrhagic exudate. What complication has developed in the patient?

- A. Carcinomatous pleuritis
- B. Acute pleural empyema
- C. Acute right-sided pleuropneumonia
- D. Right lung abscess
- E. Pulmonary embolism

136. A 37-year-old man suffers from attacks of unconsciousness, dyspnea during physical exertion, periodical sensations of heart rate disorder. Father of the patient died suddenly at the age of 45. Objectively: heart rate is 90/min., BP is 140/90 mm Hg. On heart US: ejection fraction - 55%, significant myocardium thickening of the left ventricle and interventricular septum. What drug should be prescribed for the treatment?

- A. Bisoprolol
- B. Enalapril
- C. Phenyhydinum (Nifedipine)
- D. Hydrochlorothiazide
- E. Furosemide

137. A 60-year-old man complains of discomfort when swallowing solid food, which he has been observing for a month. He changed his diet to semiliquid food products. At first the discomfort had abated but later it renewed despite the change in the diet. The patient developed gaseous eructation and hoarse voice. What examination should be performed to clarify the diagnosis?

- A. Esophagoscopy with biopsy
- B. Urea breath test for *H. pylori*
- C. Diurnal variations of ECG parameters
- D. Esophageal pH monitoring
- E. Abdominal US

138. A 22-day-old infant developed subcutaneous red nodes from 1.0 to 1.5 cm in size on the scalp; later the nodes suppurated. Temperature increased up to 37.7°C , intoxication symptoms appeared, regional lymph nodes enlarged. Complete blood count: anemia, leukocytosis, neutrocytosis, increased ESR. What diagnosis will you make?

- A. Pseudofurunculosis
- B. Pemphigus
- C. Vesiculopustulosis
- D. Scalp phlegmon
- E. -

139. A 32-year-old woman complains of general fatigue, low-grade fever persisting for 4 months, lumbar pain, and dysuria. Anamnesis includes frequent acute respiratory diseases, overexposure to cold, low-calorie diet, a case of pulmonary tuberculosis in childhood. Clinical urine analysis: pH-4.8, leukocyturia, hematuria. Complete blood count: leukocytosis, lymphocytosis, increased ESR. Urography concludes: dilatation of renal pelvis and calyceal system of both kidneys, foci of calcification in the projection of right kidney parenchyma. What is the most likely diagnosis?

- A. Nephrotuberculosis
- B. Right renal cyst
- C. Right renal carcinoma
- D. Acute glomerulonephritis
- E. Chronic pyelonephritis

140. A 45-year-old woman came to the maternity clinic with complaints of periodical pains in her mammary glands that start 1 day before menstruation and stop after the menstruation begins. Palpation of the mammary glands detects diffuse nodes predominantly in the upper outer quadrants. What is the most likely diagnosis?

- A. Fibrocystic mastopathy
- B. Breast cancer
- C. Mastitis
- D. Hyperprolactinemia
- E. Breast cyst

141. A woman complains of temperature increase up to 39°C , sharp pains in her lower abdomen, and sanguinopurulent discharge from her genital tracts. From her case history it is known that 6 days ago she underwent illegal abortion. Objectively her blood pressure is 100/60 mm Hg, pulse is 110/min. Abdominal rigidity, rebound tenderness (Bloomberg's sign), and painful palpation of the lower abdomen are observed. On bimanual examination the uterus is enlarged up to 7 weeks of pregnancy, painful, and soft; posterior vaginal fornix overhangs. Make the diagnosis:

- A. Pelvipеритоніт
- B. Endometritis
- C. Acute adnexitis
- D. Pyosalpinx
- E. Metroendometritis

142. An 8-year-old girl with complaints of painful urination, frequent low-volume urination, and leukocyturia was diagnosed with acute cystitis. 10 days before the disease onset she was treated by the gynecologist for acute vulvitis. 5 days ago she presented with mild catarrhal symptoms. Her mother ascribes the child's disease to her overexposure to cold. Specify the most likely infection route:

- A. Ascending
- B. Descending
- C. Hematogenic
- D. Contact
- E. Lymphogenic

143. A 74-year-old patient visited a urologist with complaints of pain above the pubis and inability to urinate for 8 hours. At home he had taken antispasmodics and had a warm bath but no improvement occurred. Objectively: abdomen is soft and painful above the pubis; dullness of percussion sound is observed above the pubis. Murphy's (Pasternatski's) punch sign is negative on the both sides. What condition does the patient have?

- A. Acute urinary retention
- B. Paradoxal ischuria
- C. Chronic urinary retention
- D. Anuria
- E. Oliguria

144. An excavator operator with 20 years of work experience at the opencast ore mine undergoes regular medical examination. He presents with signs of pneumoconiosis. What type of pneumoconiosis is the most likely in this case?

- A. Siderosis
- B. Silicosis
- C. Anthracosis
- D. Asbestosis
- E. Silicatosis

145. A 55-year-old woman came to a gynecologist with complaints of leukorrhea and bloody discharge from the vagina after 5 years of menopause. Anamnesis states no pregnancies. Bimanual examination: the uterus and uterine appendages are without changes. During diagnostic curettage of the uterine cavity the physician scraped off enchephaloid matter. What is the most likely diagnosis in this case?

- A. Endometrial carcinoma
- B. Adenomyosis
- C. Subserous uterine myoma
- D. Cervical carcinoma
- E. Ovarian carcinoma

146. A 5-year-old boy complains of severe dyspnea and sensation of lack of air. Objectively the child assumes orthopneic position, presents with marked peripheral cyanosis, drumstick fingers, nail plates resembling a "clock face"; the borders of cardiac dullness are bilaterally extended; coarse systolic murmur can be detected over the whole surface of the heart and is especially pronounced in the II intercostal area on the left near the sternum. What disease can be characterized by such presentations?

- A. Fallot's tetrad
- B. Dilated cardiomyopathy
- C. Defect of the interventricular septum
- D. Primary bacterial endocarditis
- E. Defect of the interatrial septum

147. A 10-year-old boy is delivered into a polytrauma unit after he received a blunt trauma of the thorax, having fallen from the bicycle. Upon hospitalization his blood pressure is 110/80 mm Hg, heart rate is 96/min. Chest X-ray is noncontributive to the diagnosis. Echocardiogram shows free liquid in the pericardial cavity, in the amount of up to 100 ml. In an hour after the hospitalization the patient started to develop increasing signs of heart failure: jugular venous distention, decreased blood pressure down to 90/70 mm Hg, tachycardia up to 120/min. On auscultation muffled heart sounds. What would be the primary tactics of a physician?

- A. Pericardiocentesis (pericardial puncture)
- B. Cardiac glycosides intravenously
- C. Constant oxygenotherapy
- D. Diuretics intravenously
- E. Antibiotics intravenously

148. A patient has gradually lost consciousness. The skin is pale and dry. There is smell of ammonia from the mouth. Respirations are deep and noisy. Heart sounds are muffled, pericardial friction rub is present. Blood pressure is 180/130 mm Hg. Blood test: Hb- 80 g/L, leukocytes - $12 \cdot 10^9/L$, blood glucose - 6.4 mmol/L, urea - 50 mmol/L, creatinine - 1200 $\mu\text{mol/L}$, blood osmolality - 350 mOsmol/kg H_2O . No urinary excretion. Make the diagnosis:

- A. Uremic coma
- B. Hyperglycemic coma
- C. Acute renal failure
- D. Acute disturbance of cerebral circulation
- E. Hyperosmolar coma

149. A 26-year-old woman has been undergoing treatment for community-acquired pneumonia for 10 days. It is known that her husband had been treated for drug addiction. Sequential intravenous administration of Amoksilav (Amoxicillin+Clavunate) + Levofloxacin combination and vancomycin in the prescribed dosage was ineffective. Within the last two days the patient's dyspnea and intoxication acutely exacerbated, bilateral pulmonary infiltrates are observed. What is the most likely cause of the medication ineffectiveness?

- A. HIV infection and pneumocystic pneumonia
- B. Tuberculosis mycobacterium infection with development of tuberculosis
- C. Idiopathic fibrosing alveolitis
- D. Infection with polyresistant bacterial strains
- E. Cancer metastases in the pulmonary tissues

150. A 35-year-old man complains of persisting enlargement of his peripheral lymph nodes that cause him no discomfort. The case history states that the first lymph nodes to enlarge were cervical, supraclavicular, and axillary; new groups of lymph nodes emerged. Objectively the lymph nodes are soft and elastic on palpation, enlarged, painless, not fixed to the surrounding tissue. What examination method would be the most informative for early diagnostics of this disease?

- A. Needle biopsy
- B. Magnetic resonance tomography
- C. Radioisotope scanning of the skeleton
- D. Ultrasound
- E. X-ray

151. A 32-year-old woman complains of body weight loss despite her increased appetite, nervousness, and tremor of the extremities. Objectively: the skin is moist; the thyroid gland is diffusely enlarged, painless, soft, and mobile. Blood test: increased level of T3, T4, and decreased thyroid-stimulating hormone (TSH). What is the most likely diagnosis?

- A. Diffuse toxic goiter
- B. Thyroid carcinoma
- C. Autoimmune (Hashimoto's) thyroiditis
- D. Thyroid adenoma
- E. Diffuse nontoxic goiter

152. A 64-year-old man suddenly sensed pain in his occipital area, dizziness, general weakness. He has a 15-year-long history of hypertension. Objectively the skin and mucosa are of normal color. Auscultation reveals vesicular respiration across the lung surface. At the cardiac apex the I heart sound is weakened, the II heart sound is accentuated over the aorta. Pulse is 84/min., blood pressure is 180/100 mm Hg. Other body organs and systems are unaffected. What drug should be prescribed in the first place?

- A. Captopril
- B. Ramipril
- C. Urapidil
- D. Perindopril
- E. Amlodipine

153. During winter epidemics of influenza caused predominantly by virus A/California/04/2009 (H1N1), on the 2nd day after the disease onset a 30-year-old hospitalized man presented with high fever, dry cough, myalgia, headache, and general weakness. What should be prescribed as etiotropic treatment in this case?

- A. Neuraminidase inhibitors (Oseltamivir)
- B. Antibiotics
- C. Immunoglobulin
- D. Interferon inducers
- E. Acyclovir

154. A 24-year-old pregnant woman on her 37th week of pregnancy has been delivered to a maternity obstetric service with complaints of weak fetal movements. Fetal heartbeats are 95/min. On vaginal examination the uterine cervix is tilted backwards, 2 cm long, external orifice allows inserting a fingertip. Biophysical profile of the fetus equals 4 points. What tactics of pregnancy management should be chosen?

- A. Urgent delivery via cesarean section
- B. Treatment of placental dysfunction and repeated analysis of the fetal biophysical profile on the next day
- C. Doppler measurement of blood velocity in the umbilical artery
- D. Urgent preparation of the uterine cervix for delivery
- E. Treatment of fetal distress, if ineffective, then elective cesarean section on the next day

155. During regular preventive gynecological examination a 30-year-old woman was detected to have dark blue punctulated "perforations" on the vaginal portion of the uterine cervix. The doctor suspects endometriosis of the vaginal portion of the uterine cervix. What investigation method would be most informative for diagnosis confirmation?

- A. Colposcopy, target biopsy of the cervix
- B. US of the lesser pelvis
- C. Hysteroscopy
- D. Curettage of the uterine cavity
- E. Hormone testing

156. A 26-year-old woman came to a gynecologist for a regular check-up. She has no complaints. Per vaginam: the uterus lies in anteflexion, not enlarged, dense, mobile, painless. On the left from the uterus in the area of uterine appendages there is a mobile painless outgrowth that can be moved independently from the uterus. On the right the appendages cannot be detected. What additional investigation would be informative for diagnosis clarification?

- A. Ultrasound of the lesser pelvis
- B. Metrosalpingography
- C. Examination for urogenital infection
- D. Colposcopy
- E. Colonoscopy

157. A 38-year-old man underwent surgical treatment of a wound with a suppuration focus. On the 8th day after the procedure the wound cleared of purulo-necrotic discharge and granulations appeared. However, against the background of antibacterial therapy, the patient's body temperature persists as high as 38.5-39.5°C; chills, excessive sweating, and euphoria are observed in the patient; heart rate is 120/min. What complication of the local suppurative inflammatory process can be suspected?

- A. Sepsis
- B. Purulent-resorptive fever
- C. Trombophlebitis
- D. Meningitis
- E. Pneumonia

158. A man complains of high fever, pain in the area of his right mastoid bone, and purulent discharge from the right ear. One week ago he had a case of URTI. Objectively the right auricle protrudes, the skin behind the ear is hyperemic and pastose; on palpation of the mastoid bone the pain intensifies; the auditory meatus is filled with thick pus, posterosuperior meatal wall sags; the tympanic membrane is red and perforated. Make the diagnosis:

- A. Acute mastoiditis
- B. Furuncle of the external auditory meatus
- C. Acute otitis media
- D. Acute otitis externa diffusa
- E. Exacerbation of chronic mesotympanitis

159. A 52 year old man came to see his family physician complaining of pain in the chest. After taking history and performing physical exam the doctor decided to direct the patient to cardiologist for a consultation. What level of medical care is being proposed to the patient?

- A. Secondary healthcare
- B. Emergency healthcare
- C. Primary healthcare
- D. Tertiary healthcare
- E. Palliative care

160. A 30-year-old woman made an appointment with the family doctor for scheduled vaccination of her 2-year-old child. What type of healthcare provides such medical services?

- A. Primary healthcare
- B. Emergency aid
- C. Secondary healthcare
- D. Tertiary healthcare
- E. Palliative care

161. A 28-year-old man after car accident received a wound to the right side of his chest inflicted by a sharp metal object. A foamy liquid flows out from the wound, there are tympanitis and acutely weakened respirations in the right. Blood pressure is 70/30 mm Hg, pulse is 120/min., Hb is 28 g/L. X-ray shows collapsed right lung, horizontal fluid level is at the 3rd rib. What treatment tactics should be chosen?

- A. Urgent thoracotomy
- B. Delayed thoracotomy
- C. Drain the right pleural cavity
- D. Apply occlusive dressing to the wound
- E. Conservative therapy

162. A 38-year-old woman has been working as a milker for 15 years. She made an appointment with the doctor due to development of red rashes on her hands, predominantly in the interdigital space. The rashes are weeping, itching, and expanding on her skin. Examination of her hands shows her nail plates to be yellow and brittle. These presentations aggravate during work. Make the provisional diagnosis:

- A. Occupational eczema
- B. Scabies
- C. Pemphigus
- D. Pyoderma
- E. Dermatophytosis

163. An 18-year-old patient complains of skin rash. The patient has been suffering from this condition for 5 years. The first instance of this disease occurred after a car accident. Objectively: the patient presents with papular rash covered in silvery scales, "thimble" symptom (small pits on the nails), affected joints. What is the most likely diagnosis?

- A. Psoriasis
- B. Panaritium
- C. Onychomycosis
- D. Lupus erythematosus
- E. Rheumatism

164. A postparturient woman, who has been breastfeeding for 3 weeks, made an appointment with the doctor. For the last 6 days she has been feeling unwell, complains of body temperature of 38-39°C, general weakness; within the last 2 days she developed pain and redness in the area of her right mammary gland.

Examination revealed her mammary gland to be significantly enlarged and deformed; breast tissue fluctuations and lymphadenitis are observed. What type of mastitis is the most likely?

- A. Phlegmonous mastitis
- B. Serous mastitis
- C. Infiltrative mastitis
- D. Lactostasis
- E. Mammary edema

165. When her car collided with a tree, a 37-year-old woman felt sharp pain in her left hip joint. She was unable to get out of the car. Her position is forced, the hip is pressed to the abdomen, fixed, and rotated inwards; the limb is flexed in the knee, any attempt to change the position results in sharp pain. Make the diagnosis:

- A. Closed dislocation of the left hip
- B. Contusion of the left hip joint
- C. Hemarthrosis of the left hip joint
- D. Arthritis of the left hip joint
- E. Closed cervical fracture of the left hip

166. On the 9th day after childbirth the obstetric patient developed high fever up to 38°C. She complains of pain in the right mammary gland. The examination revealed the following: a sharply painful infiltrate can be palpated in the right mammary gland, the skin over the infiltrate is red, subareolar area and nipple are swollen and painful. What is your diagnosis?

- A. Abscess of the right mammary gland
- B. Mastopathy
- C. Cancer of the right mammary gland
- D. Serous mastitis
- E. Fibrous cystic degeneration of the right mammary gland

167. During reanimation procedures an attempt to intubate trachea was made. Neither glottis nor epiglottis can be visualized via laryngoscopy. What tactics should be chosen in this case?

- A. Insert a laryngeal mask
- B. Perform a bag-valve-mask ventilation with Ambu bag
- C. Continue the attempts until the intubation is successful
- D. Temporarily cease the chest compressions to make intubation easier
- E. Discontinue the attempts for mechanical ventilation

168. A 48-year-old woman developed insomnia, depressive mood, anxiety, fears and suicidal thoughts after the death of her husband that occurred one month ago. During her stay in the hospital she speaks in a low voice, is depressed, anxious, avoids sleeping, refuses to eat. What medications should be prescribed in this case?

- A. Antidepressants
- B. Antipsychotics
- C. Group B vitamins
- D. Nootropics
- E. Anticonvulsants

169. A 39-year-old man suffers from chronic adrenal insufficiency and receives replacement glucocorticoid therapy (hydrocortisone - 15 mg/day). He is to undergo elective surgery for calculous cholecystitis. What medication adjustment should be made on the day of the surgery to prevent the development of acute adrenal insufficiency?

- A. Increase the dosage by 2-3 times
- B. Cancel the drug for the day of the surgery
- C. Add mineralocorticoid
- D. Add antibiotic
- E. Prescribe large volume intravenous fluid infusion

170. A 22-year-old man at 18:00 developed persisting dull pain in the epigastrium. Three hours later nausea appeared, he vomited once. By the morning the pain shifted to the right iliac area. Body temperature rose to 38.6°C , developed tachycardia of 110/min. On examination there are muscle rigidity and Bloomberg's sign (rebound tenderness) in the right iliac area of the anterior abdominal wall. Plain x-ray of the abdomen shows no fluid levels, free air under the diaphragm on the right. Make the diagnosis:

- A. Perforation of a gastric ulcer
- B. Renal colic
- C. Acute appendicitis
- D. Acute pancreatitis
- E. Acute cholecystitis

171. 40-50 minutes after the completion of repair works conducted in a closed garage, with car engine running, the repair workers developed severe headache in the temporal area, nausea, tinnitus, vertigo, etc. These symptoms are characteristic of acute poisoning with:

- A. Carbon monoxide
- B. Aldehydes
- C. Organochlorides
- D. Hydrogen sulfide
- E. Fluoride

172. After a long drive with the window open a man developed facial asymmetry; he cannot close his right eye, his right nasolabial fold is smoothed out, movements of expression are absent on the right, there is a disturbance of gustatory sensation in the tongue on the right. No other neurological pathologies were detected. What disease can be provisionally diagnosed in this patient?

- A. Neuropathy of the facial nerve
- B. Neuropathy of the trigeminal nerve
- C. Trigeminal ganglionitis
- D. Neuropathy of the oculomotor nerve
- E. Ischemic stroke

173. On ultrasound of the thyroid gland, a 47-year-old woman presents with a hypoechoic node 1.6 cm in diameter with blurred margins and intranodular hypervascularization. The doctor suspects thyroid carcinoma. What method should be used to verify the diagnosis?

- A. Fine-needle aspiration biopsy
- B. Thyroid scintigraphy
- C. Case monitoring
- D. Determine TSH level in the blood
- E. Positron emission tomography (PET)

174. A 19-year-old young man complains of cough with expectoration of purulent sputum in amount of 100 ml per day, hemoptysis, dyspnea, increased body temperature up to 37.8°C , general weakness, weight loss. The patient's condition has been persisting for 4 years. Exacerbations occur 2-3 times per year. The patient presents with malnutrition, pale skin, cyanosis of the lips, drumstick (clubbed) fingers. Tympanic percussion sound in the lungs, weakened respiration, various numerous moist crackles in the lower pulmonary segments on the left can be observed. In blood: erythrocytes - $3.2 \cdot 10^{12}/\text{L}$, leukocytes - $8.4 \cdot 10^9/\text{L}$, ESR- 56 mm/hour. On X-ray: lung fields are emphysematous, the left pulmonary root is deformed and dilated. What is the most likely diagnosis?

- A. Multiple bronchiectasis of the left lung
- B. Chronic left-sided pneumonia
- C. Chronic abscess of the left lung
- D. Left-sided pulmonary cystic dysplasia
- E. Suppuration of the cyst in the left lung

175. An 8-year-old child presents with blood pressure up to 180/100 mm Hg in the upper limbs accompanied by headaches, tinnitus, occasional nosebleeds, and high fatigability. On examination there is no pulse over the leg arteries. ECG shows left ventricular hypertrophy. MRI-scan shows aortic narrowing to 5 mm in the typical place. Coarctation of aorta is diagnosed. What kind of treatment should be prescribed in this case?

- A. Surgical
- B. Conservative
- C. Physical therapy
- D. Case monitoring
- E. Abstain from surgery in favor of complex conservative therapy

176. A 6-year-old girl arrived to the in-patient unit with complaints of enlargement of the lower third of her right thigh. According to the case history, she has been stepping carefully on her right leg and limping for 6 months. Blood test detected anemia. X-ray of the right thigh shows a round bone defect with clear margins resembling melting sugar in the distal metaphysis. What provisional diagnosis can be made in this case?

- A. Osteogenic sarcoma of the right femur
- B. Rheumatoid arthritis of the right knee joint
- C. Acute hematogenous osteomyelitis of the distal femoral metaphysis on the right
- D. Tuberculous osteitis of the distal femoral metaphysis on the right
- E. Giant cell tumor of the right femur

177. A 37-year-old man working as a typesetter in a print shop complains of rapid fatigability, paroxysmal attacks of stomachache, weak drooping hands. Examination of neurological status revealed hypotrophy of the forearm muscles. Carporadial reflexes are sharply weakened. Sensitivity is not disturbed. Gums present with dark blue border. What neurological pathology is it?

- A. Lead polyneuropathy
- B. Guillain-Barre syndrome (postinfectious polyneuritis)
- C. Shingles
- D. Ulnar neuropathy
- E. Brachial plexitis

178. The mother of an epileptic son complains of her son periodically presenting with irritable depression, when he becomes excited and prone to physical aggression and violence. These moods last for 5-10 minutes, after which the patient exhausts himself and falls asleep. Upon waking he is depressed, sad, cannot recall his actions or recalls them only partially. What psychopathologic condition is it?

- A. Dysphoria
- B. Dysthymia
- C. Epileptic delirium
- D. Pathologic affect
- E. Ambulatory automatism

179. A 44-year-old woman has undergone subtotal thyroid resection due to diffuse toxic goiter. On the second day after the surgery the patient's condition deteriorated; she developed palpitations, dyspnea, sweating, and diarrhea, and became fearful. The patient is anxious, her skin is moist and hot to the touch. Her temperature is 39.2°C . Heart sounds are muffled, tachycardia is observed, pulse is 160/min., blood pressure is 85/40 mm Hg. The stomach is soft and painless. What should be measured to clarify the patient's condition?

- A. Thyroid hormones
- B. Blood sugar
- C. 17-KS and 17-OCS in urine
- D. Blood epinephrine and norepinephrine
- E. Serum transaminases

180. The dermatologist has an appointment with a 30-year-old man that complains of severely itching rashes that especially disturb him at night. The rashes developed 2 weeks ago, after he had returned from a travel. Objectively on the lateral surfaces of his fingers, hands, wrists, elbows, lower abdomen, genitals, and thighs there are paired papulovesicles, single pustules, and scratch marks. What disease can be suspected?

- A. Scabies
- B. Pyoderma
- C. Dermatitis
- D. Eczema
- E. Shingles

181. A 28-year-old man, a teacher, after emotional stress developed painful muscle spasms in his right hand that occur during writing; now he has to hold the pen between the second and third fingers. He has no problems with typing or writing on the blackboard; no other motor disturbances or neurological pathologies are detected. What is the most likely diagnosis?

- A. Writer's cramp
- B. Cortical agraphia
- C. Parkinsonism
- D. Neuropathy of the right ulnar nerve
- E. Neuropathy of the right radial nerve

182. A 32-year-old pregnant woman at the term of 5-6 weeks was vaccinated against influenza along with her whole family. At that time she was not aware of her pregnancy. The pregnancy is wanted. The woman needs an advice from the family doctor regarding the maintenance of her pregnancy, namely whether there is a risk of fetal malformations because of received vaccination. What advice should the doctor give in this case?

- A. Vaccination against influenza is safe during pregnancy
- B. Therapeutic abortion is recommended
- C. Immediate ultrasound of the lesser pelvis is necessary
- D. Test for antibodies against influenza virus is necessary
- E. An infectious diseases specialist must be consulted

183. A 15-year-old girl suffers from systemic lupus erythematosus and has been receiving prednisolone therapy in the daily dosage of 2 mg/kg for the last 6 weeks. The plans are made to gradually lower the dosage of the medicine. No clinical signs of her disease are observed. Previously she has received no immunization against measles. Due to measles outbreak it is necessary to develop the immunity against this infection in the patient. When can she be vaccinated?

- A. At the present time
- B. After 2 weeks of prednisolone therapy in the dosage lower than 2 mg/kg/24 hours
- C. 1 month after the prednisolone therapy is complete
- D. Immediately after the prednisolone therapy is complete
- E. Never due to medical contraindications

184. A 45-year-old veterinary worker has made an appointment with the doctor for regular examination. In his duties he frequently deals with animals, however he denies working with rabies-affected animals. Previously he has received no antirabic vaccination. What should the doctor recommend in this case?

- A.** Preventive immunization with antirabic vaccine
- B.** Vaccination in case of contact with sick animal
- C.** Preventive immunization with rabies immunoglobulin
- D.** Administration of antirabic vaccine and rabies immunoglobulin
- E.** Preventive immunization with anti-rabies serum

185. A healthy child 1 year and 5 months of age is being vaccinated against hepatitis B. The child did not receive the first dose of the vaccine previously, while in the maternity hospital. The doctor makes an individual vaccination schedule for this child and plans the administration of the next dose of the vaccine. What is the minimum interval between doses of vaccine in this case?

- A.** 1 month
- B.** 6 months
- C.** 2 months
- D.** 3 months
- E.** 12 months

186. A 46-year-old man came to the surgeon's office. He complains of twitching sensation in the wound on his left foot, insomnia, and anxiety. According to the patient, he received this wound 5 days ago, when he accidentally stepped on a glass shard, while on the beach. He requested no medical assistance. Objectively the patient's general condition is satisfactory, pulse is 75/min., blood pressure is 130/80 mm Hg, temperature is 36.9°C. On the plantar surface of his foot there is a wound 1.5 cm long and up to 3 cm deep. The wound edges are moderately hyperemic, no discharge from the wound is observed. What disease can be suspected in this patient?

- A.** Tetanus
- B.** Diphtheria
- C.** Anthrax
- D.** Fasciitis
- E.** Phlegmon

187. A 45-year-old woman has been suffering from rheumatoid arthritis for 10 years and takes methotrexate twice a week. What statement regarding vaccination against pneumococci (23-valent vaccine) would conform to the recommendations for the management of rheumatoid arthritis issued by the European League Against Rheumatism in 2010?

- A.** Vaccination is recommended
- B.** Vaccination is not recommended
- C.** Vaccination is contraindicated to the patients who take methotrexate
- D.** Vaccination is contraindicated in cases when inflammatory process is active
- E.** Vaccination necessitates increase in the dosage of the long-term medicines

188. A 65-year-old woman was diagnosed with the following: chronic rheumatic heart disease, I degree of rheumatic activity; combined mi-

tral heart disease with prevalence of III degree stenosis; heart failure IIA with retained left ventricular ejection fraction, functional class III (NYHA). What tactics of vaccination against respiratory infections should be chosen to provide secondary prevention of exacerbations and to avoid heart failure decompensation in this patient?

- A.** Scheduled yearly vaccination against influenza and pneumococci
- B.** Vaccination should be combined with antibiotic administration
- C.** Vaccination is contraindicated due to severe heart failure
- D.** Any vaccination is contraindicated due to elderly age of the patient
- E.** Any vaccination is contraindicated due to mitral valve disease

189. A 69-year-old woman was diagnosed with the following: ischemic heart disease; stable exertional angina pectoris, FC III; heart failure IIA with retained left ventricular ejection fraction, functional class III (NYHA). What vaccine should be chosen for influenza prevention and to avoid destabilization of the patient's condition?

- A.** Type of influenza vaccine is not important
- B.** Inactivated influenza vaccine (IIV)
- C.** Recombinant influenza vaccine (RIV)
- D.** Vaccination is contraindicated due to severe heart failure
- E.** Vaccination is contraindicated due to elderly age of the patient

190. A 60-year-old man presents with subcompensated viral liver cirrhosis (HCV), Child-Pugh class B. What tactics should be chosen regarding the vaccination against influenza in this case?

- A.** Scheduled yearly vaccination
- B.** In case of influenza outbreak
- C.** Combined with antiviral drugs
- D.** Contraindicated due to disease progression stage, as shown by Child-Pugh class
- E.** Contraindicated due to elderly age of the patient

191. A 20-year-old student was brought to the first-aid center. He has a closed fracture of the left forearm and a contused lacerated wound on his left shin. After the patient received initial wound management, he presented the documents confirming that he has received all the necessary preventive vaccination as scheduled. What should the doctor do to prevent tetanus in this patient?

- A.** Dynamic case monitoring
- B.** Administration of tetanus immunoglobulin
- C.** Administration of anti-tetanus serum
- D.** Antibiotic therapy
- E.** Administration of tetanus toxoid

192. A 17-year-old girl has made an appointment with the doctor. She plans to begin her sex life. No signs of gynecological pathology

were detected. In the family history there was a case of cervical cancer that occurred to the patient's grandmother. The patient was consulted about the maintenance of her reproductive health. What recommendation will be the most helpful for prevention of invasive cervical cancer?

- A. Vaccination against human papillomavirus (HPV)
- B. Vitamins, calcium, omega-3
- C. Immunomodulators
- D. Antiviral and antibacterial drugs
- E. Timely treatment of sexually transmitted diseases

193. A 6-month-old infant is not vaccinated. The physician recommends a DPT (diphtheria, pertussis, tetanus) vaccination but the mother is absolutely against this procedure. Choose the most substantial argument in favor of vaccination:

- A. Risk of lethal consequences
- B. Epidemic risk for the others
- C. Personal professional experience
- D. High quality of vaccines
- E. -

194. In autumn a 45-year-old man was recommended an elective surgery for coronary artery bypass grafting due to multivessel coronary artery disease. The patient has never received anti-influenza vaccination. Why would the family doctor offer a scheduled yearly vaccination against influenza to this patient?

- A. Decrease the risk of mortality due to pneumonia and heart failure
- B. Secondary prevention of exacerbations of chronic ischemic heart disease
- C. Immunoprophylaxis of postoperative pulmonary complications
- D. Primary prevention of influenza during postoperative care
- E. Prevention of seasonal influenza

195. A 28-year-old woman has made an appointment with the family doctor to receive vaccination against influenza. However, having collected the patient's medical history, the doctor claimed this procedure to be absolutely contraindicated for this woman. What anamnestic data is the absolute contraindication to vaccination?

- A. Egg white intolerance
- B. Pregnancy at 30 weeks
- C. Blood hemoglobin - 109 g/L
- D. Body temperature - 37.2°C
- E. Psoriasis in the remission phase

196. A 26-year-old man complains of chills, rhinitis, dry cough, and fever up to 38°C. Examination shows him to be in a moderately severe condition; there are small pale pink non-merging spots on the skin of his back, abdomen, and extremities. Palpation reveals enlarged occipital and axillary lymph nodes. No information about vaccination history could be obtained. What is the likely etiology of this di-

sease?

- A. Rubella virus
- B. Epstein-Barr virus
- C. Streptococcus
- D. Mumps virus
- E. Neisseria meningitis

197. During administration of planned DPT vaccination the child suddenly developed acute anxiety, signs of pain response, dyspnea, grunting respirations, cutis marmorata, cold sweat. Objectively the child's consciousness is disturbed, heart rate is 150/min., blood pressure is 60/40 mm Hg, heart sounds are muffled. The child was diagnosed with anaphylactic shock. What drug should be administered first?

- A. Epinephrine
- B. Lasix (Furosemide)
- C. Suprastin (Chloropyramine)
- D. Euphylline (Aminophylline)
- E. Analgin (Metamizole)

198. Among first-year schoolchildren there was a case of measles registered. A 7-year-old boy from the same group was not vaccinated against measles due to refusal of his parents. His clinical history has no cases of measles in the past and is not contraindicatory to immunobiological agents. Choose the most rational tactics of measles prevention in this schoolboy:

- A. Measles-Mumps-Rubella vaccine
- B. Isolation for 20 days
- C. Antiviral agents
- D. Antibiotics
- E. Immunomodulators

199. A 40-year-old man developed fever up to 37.5°C and macular rash 10 days after the first dose of MMR (Measles-Mumps-Rubella) vaccine was administered. The vaccination was considered necessary as there was a measles outbreak in the city and the patient had not received MMR vaccination in his childhood. Is revaccination with MMR vaccine possible?

- A. Possible
- B. Forbidden
- C. After a course of glucocorticoids treatment
- D. Simultaneously with antihistamines
- E. Under supervision in the infectious diseases inpatient ward

200. A 26-year-old man is undergoing a regular check-up. One year ago he had a case of tonsillar diphtheria complicated with myocarditis. Presently his condition is satisfactory, no signs of cardiovascular failure; ECG shows first-degree atrioventricular block. What vaccine was administered to this man according to his age?

- A. Adsorbed diphtheria tetanus vaccine (modified)
- B. Acellular DPT vaccine
- C. Tetanus anatoxin
- D. Oral polio vaccine (OPV)
- E. BCG vaccine

Laboratory values

Complete blood count

Laboratory value	Normal reference range
Erythrocyte count	Male: $4.3 - 5.9 \cdot 10^{12}/L$
	Female: $3.5 - 5.5 \cdot 10^{12}/L$
Hemoglobin, blood	Male: 135-175 g/L
	Female: 120-160 g/L
Color index	0.85- 1.05
Reticulocyte count	0.5 - 1.5%
Platelet count	$150 - 400 \cdot 10^9/L$
Leukocyte count	$4.0 - 9.0 \cdot 10^9/L$
Basophils	$0 - 0.065 \cdot 10^9/L$ (0-1%)
Eosinophils	$0.02 - 0.30 \cdot 10^9/L$ (0.5 - 5.0%)
Band neutrophils	$0.04 - 0.30 \cdot 10^9/L$ (1 - 6%)
Segmented neutrophils	$2.0 - 5.50 \cdot 10^9/L$ (47 - 72%)
Monocytes	$0.09 - 0.60 \cdot 10^9/L$ (3 - 11%)
Lymphocytes	$1.2 - 3.0 \cdot 10^9/L$ (19 - 37%)
Erythrocyte sedimentation rate (ESR)	Male: 0 - 15 mm/h
	Female: 0 - 20 mm/h
Hematocrit	Male: 41 - 53%
	Female: 36 - 46%

Biochemical blood analysis (Metabolic panel)

Total proteins	60-78 g/L
Albumin	35-50 g/L (52-65%)
Globulin:	23-35 g/L (35-48%)
α_1 -Globulin	2-4 g/L (4.2-7.2%)
α_2 -Globulin	5-9 g/L (6.8-12%)
β -Globulin	6-11 g/L (9.3-15%)
γ -Globulin	11-15 g/L (15-19%)
Immunoglobulins:	
IgD	0 - 0.15 g/L
IgG	6.5-15 g/L
IgM	0.4-3.45 g/L
IgA	0.76-3.90 g/L
IgE	0-380 kU/L
Bilirubin:	
Total	2-17 $\mu\text{mol}/L$
Indirect (unconjugated)	2-17 $\mu\text{mol}/L$
Direct (conjugated)	0-5 $\mu\text{mol}/L$
Triglycerides	0.59-1.77 mmol/L
Total cholesterol	3.9-6.2 mmol/L
Lipoproteins:	
high-density lipoproteins (β -Lipoproteins)	<4.2 mmol/L
low-density lipoproteins (α -Lipoproteins)	0.8-1.8 mmol/L
Glucose, blood	3.3-6.1 mmol/L (fasting)
Glycated hemoglobin	6%
Iron, blood	9-30 $\mu\text{mol}/L$
Potassium, plasma	3.5-5.0 mmol/L
Sodium, plasma	136-145 mmol/L
Calcium, plasma	0.75-2.5 mmol/L

Magnesium, plasma	0.75 - 1 mmol/L
Phosphorus (inorganic), serum	0.646-1.292 mmol/L
Chloride, blood	95-105 mmol/L
Urea, serum	3.33 - 8.32 mmol/L
Creatinine	53 - 106 mcmol/L
Uric acid	Male: 0.12-0.38 mcmol/L Female: 0.12-0.46 mcmol/L
Lactate dehydrogenase (LDH)	45-90 U/L
α -Amylase (diastase), blood	25-125 U/L
Aspartate aminotransferase (AST)	15-40 U/L
Alanine aminotransferase (ALT)	10-40 U/L
Phosphatase (alkaline)	30-115 U/L

Coagulogram

Prothrombin time	80-100% (< 12 seconds)
Fibrinogen	2-4 g/L
Partial thromboplastin time (activated)	< 28 seconds
Lee-White coagulation time	5-10 minutes
Bleeding time (Duke method)	< 4 minutes

Acid-base balance

pH arterial blood	7.35-7.45
Pco ₂ arterial blood	33-45 mm Hg
Po ₂ arterial blood	75 - 105 mm Hg
Bicarbonate, blood (HCO ₃)	22-28 mmol/L

Other blood values

Cortisol, serum	230 - 750 nmol/L
Osmolality, serum	275 - 295 mOsmol/kg H ₂ O
Thyroid-stimulating hormone, serum or plasma	0.5-5 mIU/L
Thyroxine (T ₄), serum	65-155 nmol/L
Triiodothyronine (T ₃), serum	1.77 - 2.43 nmol/L
Ferritin, serum	Male: 15-200 mcg/L Female: 12-150 mcg/L
Thymol turbidity test	< 5 U
C-reactive protein (CRP)	<6 mg/dL
Antistreptolysin 0 (ASL ₀)	250 U
Antistreptohyaluronidase (ASH)	250 U

Urine

Urine specific gravity	1.016-1.022
Nechiporenko's test:	
leukocytes	< 2 · 10 ⁶ /л
erythrocytes	< 1 · 10 ⁶ /л
Proteins, total	<45.0 - 75.0 mg/24 h (<0.033 g/L)
Calcium	2.5 - 7.5 mmol/24 h
Creatinine clearance	Male: 97 - 137 mL/min Female: 88 - 128 mL/min
Oxalate	90 - 445 mcmol/L
17-Ketosteroids (17-KS)	Male: 27.7 - 79.7 mcmol/24 h Female: 17.4 - 55.4 mcmol/24 h
17-Hydroxycorticosteroids (17-OCS)	5.5 - 27.6 mcmol/24 h
α -Amylase (diastase), urine	28-160 U/L

INSTRUCTIONAL BOOK

Testing Board

TEST ITEMS FOR LICENSING EXAMINATION: KROK 2. MEDICINE.

Kyiv. Testing Board.
(English language).

Approved to print 12.04/№214. Paper size 60x84 1/8
Offset paper. Typeface. Times New Roman Cyr. Offset print.
Conditional print pages 28. Accounting publishing pages 32.
Issue. 2493 copies

List of abbreviations

ACTH	Adrenocorticotrophic hormone
ADP	Adenosine diphosphate
ALT, ALAT	Alanin aminotranspherase
ALV	Artificial lung ventilation
AP	Arterial (blood) pressure
AST, AspAT	Aspartat aminotranspherase
ATP	Adenosine triphosphate
BCG	Bacillus Calmette-Guérin
BP	Blood (arterial) pressure
CK	Creatine kinase
CNS	Central nervous system
CoA	Coenzyme A
CRP	C-reactive protein
CT	Computed tomography
COX	Cyclooxygenase
DIC	Disseminated intravascular coagulation
DTP (DPT)	Diphtheria-tetanus-pertussis vaccine
EDTA	Ethylenediamine tetra-acetic acid
ELISA	Enzyme-linked immunosorbent assay
ENT	Ear, nose, and throat (as a department in a hospital)
EPR (ER)	Endoplasmic reticulum
ESR	Erythrocyte sedimentation rate
EV	Enterovirus
FC	Functional class
GABA	Gamma aminobutyric acid
Hct, Ht	Hematocrit
HDL	High-density lipoproteins
HR	Heart rate
IDL	Intermediate-density lipoproteins
IU	International unit
IUPAC	International Union of Pure and Applied Chemistry
LDH	Lactate dehydrogenase
LDL	Low-density lipoproteins
LOX	Lipoxygenase
MAO	Monoamine oxidase
MRI	Magnetic resonance imaging
NSAID	Nonsteroidal anti-inflammatory drug
PE (PATE)	Pulmonary embolism (Pulmonary artery thromboembolism)
PSA	Prostate-specific antigen
RBC	Red blood count
RR	Respiratory rate
SES	Sanitary-and-epidemiologic station
STD	Sexually transmitted disease
STI	Sexually transmitted infection
T/l	Trillion/liter
TABT	Typhoid-paratyphoid A and B plus tetanus toxoid vaccine
TMJ	Temporomandibular joint
TSH	Thyroid-stimulating hormone
TU	Tuberculin unit
URTI	Upper respiratory tract infection
V/f	Vision field
VLDL	Very-low-density lipoproteins
WBC	White blood count
WPW	Wolff-Parkinson-White syndrome