

Algorithms for the exam of the discipline “Pediatrics surgery”

Station: “Surgery. Practical skills”

1. Pneumoirigography methodology and interpretation in case of suspected intestinal intussusception in an infant.

1. Establish the absence of contraindications to manipulation (peritonitis, age older than 2 years, duration of symptoms more than a day, recurrent intussusception).
2. The position of the child on his back.
3. The tip of the Richardson balloon is covered with a lubricant.
4. A tip of an catheter with an obturator is inserted into the rectum.
5. Under X-ray control, gently pump air (40-65 mm Hg), using a Richardson balloon and monitor its gradual spread through the colon.
6. Evaluated the results. Indicate the presence of an intussusception:
 - 1) air passage blockage;
 - 2) shadow of intussusception in the form of “cockade”, “sickle”, “trident”, etc.The invaginate is clearly visible against the background of the gas in the form of a rounded shadow with clear contours, often in the region of the hepatic flexure.
7. Show the presence of factors predisposing to intussusception (dolichosigma, dolichocolon).

2. Assistance (conservative measures) for a child with late adhesive intestinal obstruction.

1. Cancellation of enteral nutrition
2. Provision of venous access
3. Infusion therapy (providing physiological need for fluid) 5 ml / kg / h
4. Formation of nasogastric tube fr 8-10.
5. Performing a cleansing enema.
6. Stimulation of intestinal peristalsis with a solution of Proserine 0,5% (in the age dose)
7. Monitoring of hemodynamics and therapy correction saturation
8. Introduction of water-soluble contrast.

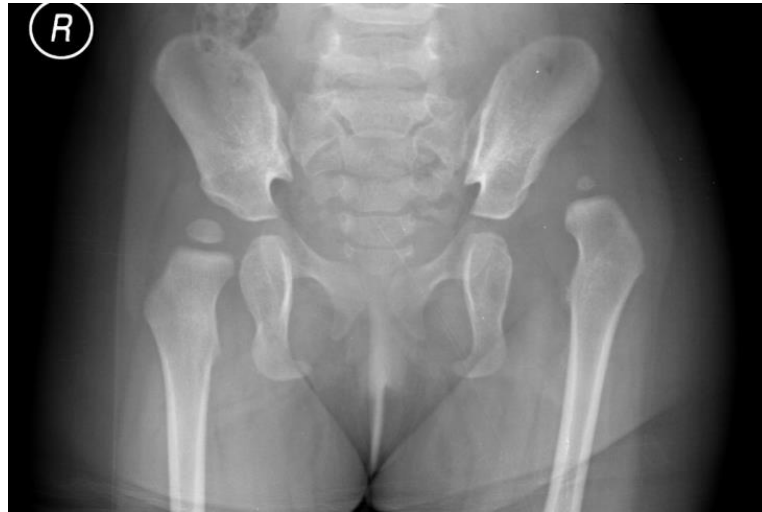3. Providing initial care to a newborn with atresia of the esophagus at the stage of transportation to the surgical hospital.

1. Cancellation of enteral nutrition.
2. Establish of venous access
3. Tracheal intubation.
4. Artificial lung ventilation.
5. Infusion therapy (providing physiological maintenance of fluids) 5 ml / kg / h
6. Active aspiration of the content from the proximal segment of the esophagus through the probe Fr 8 (every 10-15 minutes).
7. Transportation with raised head end
8. Registration of a detailed medical case record.
9. Informing and obtaining the written consent of the mother for possible surgical treatment.
10. Compliance with the principle of the thermal circuit (transportation in the cuvese).
11. Vitamin K (1 mg)
12. Antibacterial prophylaxis.
12. Inotropic support (if indicated)
13. Monitoring of hemodynamics and saturation with therapy correction.

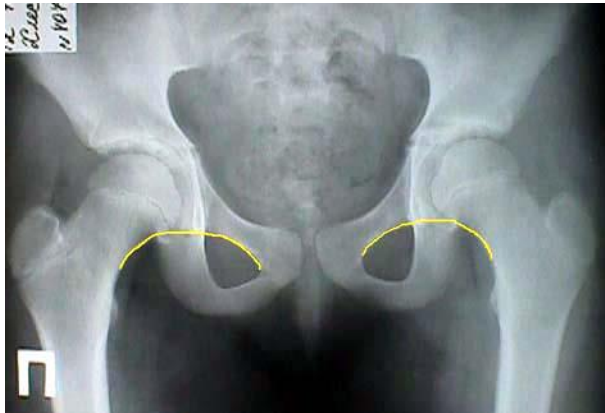4. Providing initial care to a newborn with upper congenital intestinal obstruction at the stage of transportation to a surgical hospital.

1. Cancellation of enteral nutrition
2. Establish of venous access
3. Infusion therapy (providing physiological maintenance for fluids) 5 ml / kg / h
4. Insertion of nasogastric tube fr 8-10.
5. Registration of a detailed medical case record.
6. Informing and obtaining the written consent of the mother for possible surgical treatment.
7. Compliance with the principle of the thermal circuit (transportation in the cuvette).
8. Vitamin K (1 mg)
9. Inotropic support (as indicated)
10. Monitoring of hemodynamics and saturation with subsequent correction of therapy as needed.

1. Interpretation of a radiograph of a patient with developmental hip dysplasia.



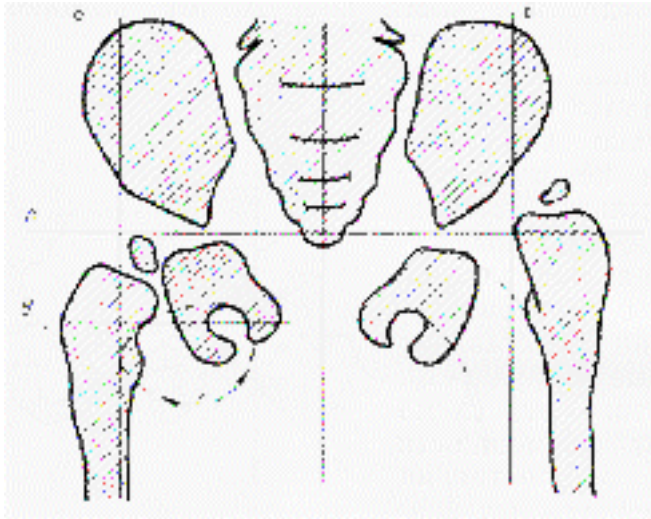
1. Evaluate and indicate on the radiograph the presence, symmetry of the ossification point of the femoral heads, correlation with age.



2. Draw a Shanton line — the line connecting the lower edge of the femoral neck and the upper edge of the obturator hole. Normally, a continuous arcuate line is formed. With subluxation and dislocation - the thigh neck is shifted up, the curved line is interrupted.

3. Reinberg-Higelreiner Scheme: draw a horizontal line A through the Y-shaped cartilage.

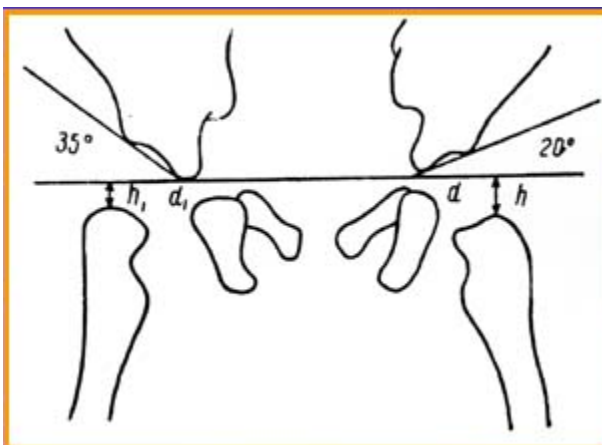
4. Then, draw a line B and the median line through the superior lateral protrusion of the acetabulum.



5. The position of the ossification point of the femur head is estimated. Normally, the point of the ossification of the femoral head is placed in the lower inner quadrant. With subluxation - in the outer lower quadrant.

With a dislocation - in the outer upper quadrant.

2. Draw a line through the roof of the acetabulum.



3. Measure the acetabular angle (the angle of the roof of the cavity formed by the intersection of the line drawn through the U-shaped cartilage and the tangent passing along the upper edge of the articular cavity). Normally, in children up to 3 months of age it is less than 30° and decreases to 20 degrees by the year. It is more accurately determined using the normative table (attached).

4. Formulate the Putti triad (1) the late formation of ossification foci; 2) supra lateral position of the femoral head; 3) the sloping roof of the acetabulum (acetabular index))

5. To assess the presence and degree of developmental hip dysplasia in a child in accordance with the specified criteria.