

## Medical history taking

### Preparation of the patient and equipment for the examination:

- 1) say hello to the patient;
- 2) name yourself;
- 3) ask how to refer to him;
- 4) offer comfortable sitting down;
- 5) prepare the necessary medical documentation;
- 6) provide during the conversation isolation from the effects of various irritants (extraneous conversations, phone calls, etc.);
- 7) sit next to the table.

### Medical history:

- 1) find out passport data (last name, first name, middle name, age, marital status), as well as the profession and working conditions, living conditions, and enter them in the appropriate columns;
- 2) collect a medical history according to the following scheme:
  - a) the onset of the disease;
  - b) the course of the disease;
  - c) the presence of general disorders

Complaints and data on the course of the disease should be entered in the appropriate section of the medical documentation.

- 3) collect an anamnesis of life (heredity, development, diseases transferred in childhood and adulthood, bad habits, living and nutritional conditions, allergic reactions, blood transfusion, health of relatives, close relatives, children) and enter the data in the appropriate section of the medical documentation

### Assessment of anamnestic data:

- 1) highlight the main complaints that dominate the history
- 2) establish the relationship of complaints, that is, combine symptoms into syndromes
- 3) determine the nature of the course of the disease (acute, chronic);
- 4) name the probable causes that could induce the disease.

## **Determination of the visual field by the control method**

### Preparing the patient for the examination:

- 1) say hello to the patient;
- 2) name yourself;
- 3) ask how to refer to him;
- 4) explain the expediency of the examination;
- 5) obtain consent to its implementation;
- 6) offer to sit on a chair with his back to the light;
- 7) pay the patient's attention to the fact that you need to sit upright, not squint, do not tilt your head in one direction or another and look directly in front of you.

### Examination performance:

- 1) ask the patient to cover tightly with the palm his left eye;
- 2) ask the patient to have both of his eyes (covered with a palm and not covered) being opened and not moving;
- 3) sit opposite to the patient at a distance of 1 m;
- 4) cover your right eye with your own palm of your right hand;
- 5) ask the patient to look fixedly at the open left eye of the examinant, which should be directed to the right eye of the patient;
- 6) take yours straightened left hand to the left, taking a pencil in your hand and slowly move your hand in a plane in the middle of the distance between the patient and the doctor, perpendicular to the patient's visual line;
- 7) perform movements in four main directions (vertical, horizontal and two oblique)
- 8) ask the patient to indicate the moment the pencil appeared in the doctor's hand;
- 9) compare your own feelings of the appearance of a pencil with the sensations of the patient;
- 10) evaluate the result of the study;
- 11) in a similar way, examine the field of view of the patient's left eye, covering the right eye with his right palm, and your left eye with yours left; studies should be carried out with the free right hand with a pencil in it;
- 12) evaluate the result of the examination

## **Direct ophthalmoscopy (dummy)**

### Preparation of equipment for examination:

- 1) sit in front of the dummy at a distance of 50 cm, take an ophthalmoscope in your right hand, turn it on,
- 2) holding an electric ophthalmoscope in right hand, position it to the right eye, slightly resting against the upper edge of the orbit;
- 3) send a light beam with an ophthalmoscope, following the pupil of the right eye pupil of the dummy through the opening in the ophthalmoscope (conduct an ophthalmoscopic examination) to assess the state of transparency of the optical media of the eye;
- 4) at the moment when the pupil begins to glow in red, approach the right eye of the dummy to a distance of 5.0 cm, mentally directing sight into the distance;
- 5) in the absence of a clear vision of the fundus and with the transparency of the optical media of the eye by rotation of the refractive disk or tape, find a lens in which the fundus will be clearly visible;
- 6) examine the fundus in the following sequence: optic nerve disk, arcade vessels, equatorial zone, retinal periphery, macular zone;
- 7) describe the seen picture of the fundus;
- 8) turn off the ophthalmoscope.

## **Determination of intraocular pressure (palpation)**

### Preparing the patient for the examination:

- 1) say hello to the patient;
- 2) name yourself;
- 3) ask how to refer to him;
- 4) explain the expediency of the examination;
- 5) obtain consent to its implementation
- 6) wash hands; wear examination gloves.

### Examination performance:

- 1) sit opposite to the patient;
- 2) ask the patient to close his eyes and look down;
- 3) place the pads of the terminal phalanges of the index fingers of both hands on the soft part of the upper eyelid of the right eye, above the upper edge of its cartilage, and alternately pressing the eyeball through the eyelid to determine the degree of its density;
- 4) evaluate the intraocular pressure of the right eye:
  - T n - normal IOP
  - T + 1 moderate increase in pressure compared to normal
  - T + 2 significant increase in pressure, slight scleral depression is observed
  - T + 3 eyes hard as a stone, even with intense pressure it is impossible to press the sclera,
  - T-1 eye moderately mild, IOP moderately reduced
  - T-2 eye soft, IOP low
  - T-3 when pressing the eye, the finger does not feel support, IOP is significantly reduced
- 5) conduct a similar examination of the left eye.

## **Determination of the visual acuity**

### Preparing of the patient and equipment for the examination:

- 1) say hello to the patient;
- 2) name yourself;
- 3) ask how to refer to him;
- 4) explain the expediency of the examination;
- 5) obtain consent to its implementation
- 6) offer to sit on a chair that stands opposite to the table at a distance of 5 m from it;
- 7) connect the Rota apparatus to the electric network;
- 8) pay the patient's attention to the fact that you need to sit upright, not squint, do not tilt your head in one direction or another and look straight ahead.

### Examination performance:

- 1) ask the patient to cover the left eye with an opaque shutter (occluder);
- 2) in the absence of complaints of visual impairment, stand next to the table, pick up the pointer, place its tip under the randomly selected optotype of the 10 th row of the table at a distance from the last so that the shadow from the pointer does not fall on the optotype, and ask the patient to name this optotype;
- 3) the duration of the demonstration of the optotype should be 2-3 s;
- 4) the patient is asked to name the letters that he sees with his right eye in the tenth line, if he cannot recognize the letters of the tenth line, then they go up a line above and so on to the line that the patient calls with the minimum number of errors;
- 5) if the patient at a distance of 5 m, does not see the letter in the first line, then visual acuity begins to be checked using portable optotypes (Landolt rings, sticks), determining the distance from which the patient can correctly name them, and given that every half meter corresponds 0.01;
- 6) the occluder is placed in front of the right eye and the visual examination of the left eye is repeated, according to a similar scenario;

### Assessment and registration of examination results:

- 1) visual acuity corresponds to that indicated on the right next to the line of the smallest signs, which the patient named correctly (one error is allowed in 3-6 lines, and two - in 7-10 lines, but then it is indicated that visual acuity is incomplete);
- 2) the visual acuity of the right eye is indicated by Vis OD =, the left eye by Vis OS =, after the sign "=" indicate the result of the study.

## **Determination of ciliary body painfulness**

### Preparing the patient for the examination:

- 1) say hello to the patient;
- 2) name yourself;
- 3) ask how to refer to him;
- 4) explain the expediency of the examination;
- 5) obtain consent to its implementation
- 6) wash the hands; wear examination gloves.

### Examination performance:

- 1) sit opposite to the patient;
- 2) ask the patient to close his eyes and look down;
- 3) place the pads of the terminal phalanges of the index fingers of both hands on the soft part of the upper eyelid of the right eye, above the upper edge of its cartilage, and alternately pressing the eyeball through the eyelid to determine the degree of pain;
- 4) the results are recorded as follows:
  - on palpation, painfulness of the ciliary body is noted
  - ciliary body is not painful on palpation
- 5) conduct a similar examination of the left eye.

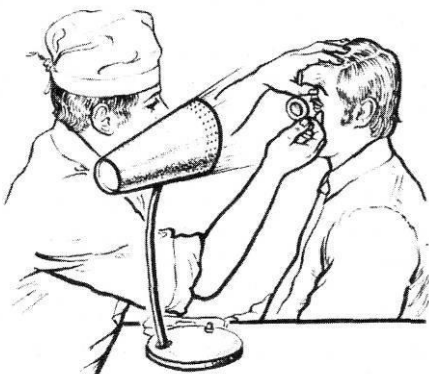## Side lighting examination

### Preparation of the patient for the examination:

- 1) say hello to the patient;
- 2) name yourself;
- 3) Ask how to refer to him;
- 4) explain the expediency of the examination
- 5) obtain consent to its implementation;
- 6) wash the hands; wear examination gloves.

### Examination performance:

- 1) the light source (desk lamp) should be installed to the left and at a distance of 50 to 60 cm from the patient at the eye level; the head of the patient should be slightly rotated towards the light source;
- 2) move the doctor's knees to the right and the patient's knees to the left;
- 3) take the lens of + 13 D in the right hand. Place it in front of the patient's eye at a distance of 7-8 cm perpendicular to the rays from the light source (an additional lens of + 20 D. may be used to consider the smaller details);
- 4) focus the lens on the region of the eye to be examined with reflected rays.
- 5) in the examination of the sclera, attention should be paid to the colour of the sclera, to the movement and to the filling of the blood vessels (white sclera, not visible at the end of the loop, to the identification of only single conjunctival vessels)



- 6) during examination of the cornea, the size, shape, transparency, sphericity, mirrority of the cornea are established (despite transparency, the normal cornea looks smoky at the side light, the surface of the cornea is smooth, shiny, the upper part of the cornea limb is enlarged).
- 7) the depth and contents of the eye's front chamber are determined (the depth of the chamber is determined by the distance between the reflexes on the cornea and on the iris, the mean depth thereof is 3-3.5 mm, the moisture is normally so transparent that the front chamber appears empty).
- 8) when studying the iris, the colour, the drawing, the presence or absence of pigment inclusions, the state of the pigment fringe, the width, the shape and the mobility of the pupil (the pupil's response to light) are noted.
- 9) the lens is visible at lateral illumination only when it is blurred.

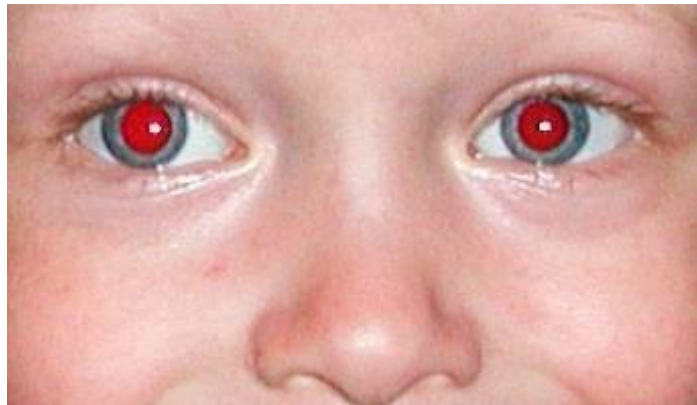
## Research method in transmitted light

### Preparation of the patient for the examination:

- 1) say hello to the patient;
- 2) name yourself;
- 3) Ask how to refer to him;
- 4) explain the expediency of the examination
- 5) obtain consent to its implementation;
- 6) wash the hands; wear examination gloves.

### Examination performance:

- 1) the examination should be carried out in a dark room, the light source being placed to the left and rear of the patient at the eye level;
- 2) the doctor sits opposite to the patient, holds an ophthalmoscope in his right hand, attaches it to his right eye and sends a beam of light to the eye of the examined person, in which it is better to dilate the pupil beforehand
- 3) when optical media are transparent, a part of the reflected rays through the ophthalmoscope opening gets into the doctor's eye and the patient's pupil «glows» with red light.
- 4) the transparency of the lens and vitreous body is assessed in terms of the intensity and uniformity of the pupil's luminance.



If the light beam reflected from the eye of the subject meets a blur, depending on the shape and density, they will delay some of the rays, and either dark spots or bands and diffuse shades will appear on the red background of the pupil. In the absence of turbidity in the cornea and the anterior chamber, which is easily ascertainable by lateral illumination, the resulting shadows will be caused by the blurring of the lens or vitreous body. The turbidity in the lens is fixed, and when the eyeball moves, they move with it. The turbidity of the vitreous body is not fixed, and when the eyeball moves (even slightly), they swim against the red light of the pupil, appearing and disappearing.



## **Examination of the eyeball mobility**

### Preparation of the patient for the examination:

- 1) say hello to the patient;
- 2) name yourself;
- 3) ask how to refer to him;
- 4) explain the expediency of the examination
- 5) obtain consent to its implementation;
- 6) propose to sit on the chair with his back to the light;
- 7) wash the hands; wear examination gloves.

### Examination performance:

- 1) sit opposite to the patient;
- 2) ask the patient to follow the object (finger, handle), which is moved by the doctor in different directions (right, left, up and down), with two eyes.
- 3) to see whether the patient's eyeballs are moving in synchrony or not and what position they occupy at the extremities.
- 4) at the maximum eye-to-nose rotation, the inside edge of the cornea shall extend to the inside corner of the eye slot and, when the eye slot is removed in the opposite direction, the corresponding edge shall contact the outer corner of the eye slot.

## **Determination of the angle of strabismus according to Hirshberg**

### Preparation of the patient for the examination:

- 1) say hello to the patient;
- 2) name yourself;
- 3) Ask how to refer to him;
- 4) explain the expediency of the examination
- 5) obtain consent to its implementation;
- 6) Propose to sit on the chair with his back to the light;
- 7) the lamp should be placed rear and left from the patient,
- 8) wash the hands; wear examination gloves.

### Examination performance:

- 1) sit in front of the patient and ask him to look directly in front of him;
- 2) take an ophthalmoscope mirror from the set and with the aid of this mirror direct the beam of light into the patient's eyes (in the non-squinting eye the reflected beam of light coincides with the center of the pupil, in the skew it will be shifted).
- 3) by the magnitude of this displacement it is possible to determine the angle of squinting (if the reflex is located at the edge of the pupil, the angle of squinting will be equal to  $15^{\circ}$ , at the edge of the pupil on the iris -  $20^{\circ}$ , between the edge of the pupil and the limb -  $25-30^{\circ}$ , on the limb -  $45^{\circ}$ , behind the limb -  $60^{\circ}$  or more).